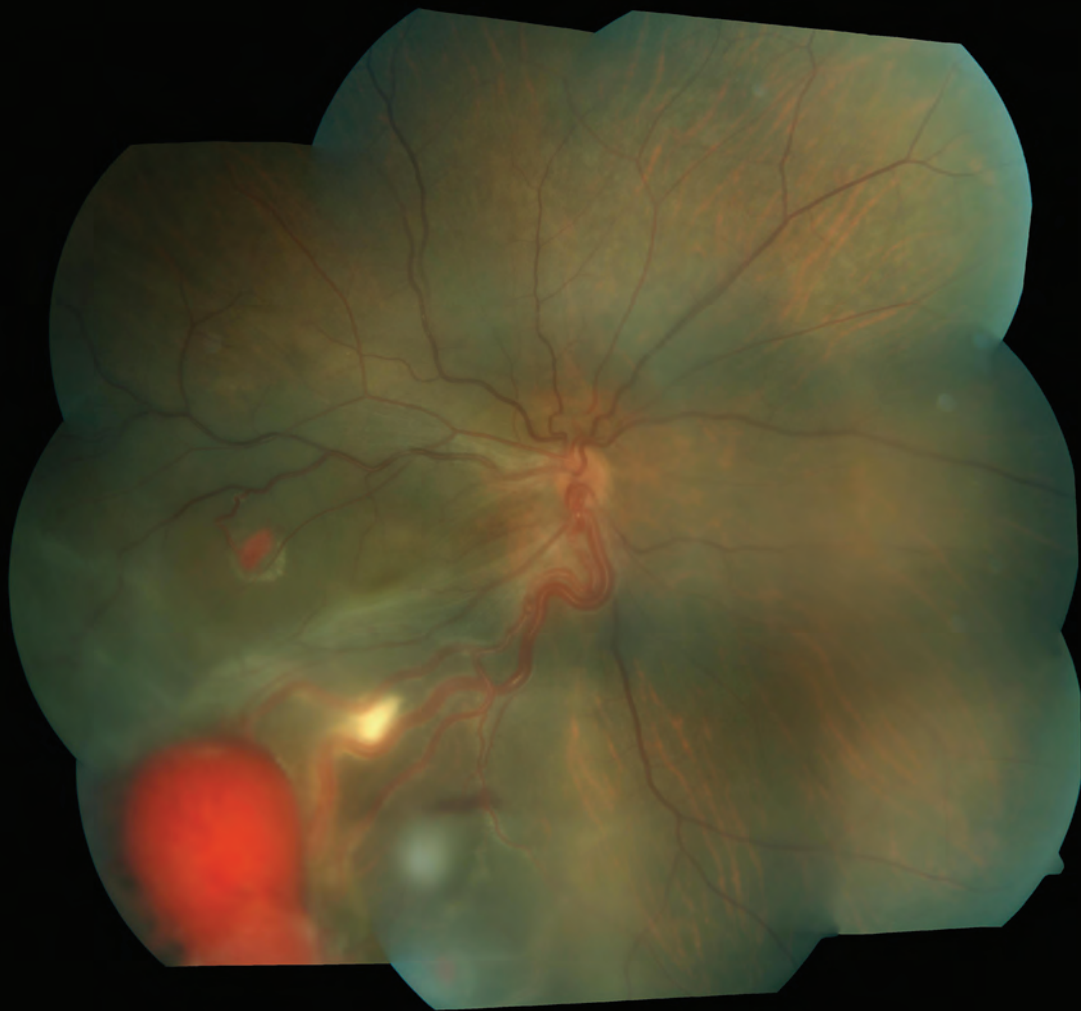

# insight

Scientific Journal of

**MEDICAL & VISION RESEARCH FOUNDATIONS**



insight

Scientific Journal of **Medical & Vision Research Foundations**

Year: 2015

Issue: Vol. XXXIII | No. 2 | June 2015 | Pages 49–113

Typeset at: Techset Composition India (P) Ltd., Chennai, India

Printed at: Gnanodaya Press, Chennai, India

©Medical and Vision Research Foundations



### Sankara Nethralaya – The Temple of the Eye.

It was in 1976 when addressing a group of doctors, His Holiness Sri Jayendra Saraswathi, the Sankaracharya of the Kanchi Kamakoti Peetam spoke of the need to create a hospital with a missionary spirit. His words marked the beginning of a long journey to do God's own work. On the command of His Holiness, **Dr. Sengamedu Srinivasa Badrinath**, along with a group of philanthropists founded a charitable not-for-profit eye hospital.

Sankara Nethralaya today has grown into a super specialty institution for ophthalmic care and receives patients from all over the country and abroad. It has gained international excellence and is acclaimed for its quality care and compassion. The Sankara Nethralaya family today has over 1400 individuals with one vision – to propagate the Nethralaya philosophy; the place of our work is an Alaya and Work will be our worship, which we shall do with sincerity, dedication and utmost love with a missionary spirit.

## Contents

<b>Guest Editorial:</b> Academics, Research and Clinical Work: the Balancing Act <i>Lingam Gopal</i>	49
<b>Preferred Practice Pattern:</b> Diabetic Macular Edema <i>Rajiv Raman and Muna Bhende</i>	50
<b>Review article:</b> Micro Incision Vitrectomy Surgery (MIVS): An Overview <i>Pramod S. Bhende and Aneesha Lobo</i>	57
<b>Preferred practice pattern:</b> Endophthalmitis: Current Trends, Drugs, and Protocols <i>Aditya Verma, Vinata Muralidharan and Eesh Nigam</i>	61
<b>Recent advances:</b> Macular Buckle in Myopia <i>Pradeep Susvar and S. Vinay Kumar</i>	71
<b>Recent advances:</b> Optical Coherence Tomography: Newer Techniques, Newer Machines <i>KP Mohana, Debmalaya Das and Muna Bhende</i>	75
<b>Preferred practice pattern:</b> Intravitreal Injection Guidelines <i>Ekta Rishi and Pramod Bhende</i>	80
<b>Recent advances:</b> Recent Advancements in Ocular Electrodiagnostics <i>Parveen Sen and Ramya Sachidanandam</i>	83
<b>Recent advances:</b> Genetic Testing for Eye Diseases <i>Vikas Khetan</i>	87
<b>Recent advances:</b> Update on Intraocular Oncology <i>Suganeswari Ganesan</i>	88
<b>Review article:</b> Retinopathy of Prematurity: An Update <i>Parveen Sen, Chetan Rao and Nishat Bansal</i>	93
<b>Recent advances:</b> Current Role of Photodynamic Therapy in Ophthalmic Practice <i>Pukhraj Rishi and Vishvesh Agarwal</i>	97
<b>Recent advances:</b> Techniques of Fundus Imaging <i>Amit B. Jain, Vadivelu Jaya Prakash and Muna Bhende</i>	100
<b>Ophthalmic photography:</b> Insight Ophthalmic Photography Competition <i>Jaydeep Avinash Walinjar and Mohammadarif Mulla</i>	108
<b>Last Word:</b> Developing Clinical Empathy: <i>Enhancing Patients' Satisfaction</i> <i>Tarun Sharma</i>	



*This special issue of Insight is dedicated to our beloved Chairman Emeritus, Dr SS Badrinath who has completed his joyous journey of 75 years and carved this Fountainhead of Knowledge - the Temple of Eye - SANKARA NETHRALAYA.*

# Academics, Research and Clinical Work: the Balancing Act

## Lingam Gopal

---

### Correspondence to:

Lingam Gopal,  
Senior consultant,  
National University Hospital  
Singapore  
President,  
Vision Research Foundation  
Sankara Nethralaya  
Chennai, India  
E-mail: lingamgopal@gmail.com



Before we talk about the balancing act, let us discuss what can define each of the three activities that comprise the clinician's work schedule: clinical work, academics and research.

Clinical work can be defined as the direct interaction with patients related to the amelioration of their illness. This is perhaps the most important reason why we have qualified as doctors. Academics can be defined as acquisition and dissemination of knowledge while research can be defined as the delving into the world of unknown or partially known.

Practice of clinical medicine involves broadly speaking, diagnosing the condition, administration of medical treatment and performing surgical procedures where needed, with compassion as the main driving force. Academics as we practice involves interaction with trainees, publishing in peer reviewed journals, presentation in conferences etc. Research can be purely clinical or a combination of clinical and basic science research.

At their core however, all the three facets of our functioning would need relevant knowledge, logical thinking, sound judgment and practical experience. The knowledge acquired initially through proper training and teaching during our formative years forms a good basic foundation. However, an equal or more amount of knowledge is added by constant updating through journals, conferences, visiting senior clinicians etc. This acquisition of knowledge helps in turn to treat our patients better. One should remember that, in this era of the internet, the patients can be more informed than the clinicians about the most recent developments—since they will be concentrating on digging into information on one disease that they are interested in.

Academics helps one to keep abreast of latest developments. The preparation for lectures, interaction with the trainees, writing articles for journals, reviewing articles written by others etc. are all ways of enriching one's mind. It is not a waste of time nor is it second in its importance to clinical care. It is a vital activity to maintain one's talents as a good clinician. Hence it is not a question of clinics versus academics but clinics and academics for as long as we are practicing medicine.

I would recommend everyone to read the book by Arthur Hailey, 'The final diagnosis'. Fifty years

after it was written, it is still relevant in its message. A great pathologist had to resign in ignominy when he fails to keep up with knowledge and makes a blunder.

Research is like the icing on the proverbial cake. It is mentally stimulating and generates creativity in a person. Even the very act of trying to write a grant application is a huge learning process. A clinician–researcher cannot say he/she will not see patients but do only research. Where will the ideas come from, if one does not see enough clinical spectrum of disease? Research does not have to be always in the form of a major project. Small ideas, which can potentially improve the delivery of health care or make it more efficient, can also be research projects. Interaction between clinicians and basic scientists creates a fertile ground for generating new ideas that can be converted to good-quality research projects.

Having said that, research can still be optional. There may be many reasons why a clinician may not be able to indulge in research—interest or lack of it, available time, priorities etc.

Balancing is a part of life in general and equally applicable to the professional life. While one can prioritize what one wants to do and what one does not want to do, there is one activity, we as clinicians are committed to do and hence duty bound to do—i.e. good patient care. To enable this to be consistently of the highest order, academics is a must.

We have to run to stay at the same place, lest we are dragged backwards and have a shameful fall. Often one offers 'lack of time' as an excuse. But more often than not—'improper utilization of time' is the cause. One should seriously ask oneself if the time off from clinical work is properly utilized. Setting long-term goals and short-term targets is a good way of proportioning this academic time and making best use of it. Research (done to any extent) tends to round off the professional satisfaction one gets. If one does not want the icing on the cake, so be it.

Broadly, one should be able to do justice if 80% of time is allocated for clinical work; 10% for academics and 10% for research, with the proviso that the time is well utilized for the purpose intended. Finally, one should remember that there is never enough of what we want—money, affection, time, power etc.

**How to cite this article** Gopal L. Academics, Research and Clinical Work: the Balancing Act, *Sci J Med & Vis Res Foun* 2015;XXXIII:49.

# Diabetic Macular Edema

## Rajiv Raman and Muna Bhende

Sri Bhagwan Mahavir  
Vitreoretinal Services,  
Sankara Nethralaya

**Correspondence to:**  
Rajiv Raman,  
Senior Consultant,  
Sri Bhagwan Mahavir  
Vitreoretinal Services,  
Sankara Nethralaya.  
Email: drrrn@snmail.org

### Introduction

Over the last one decade the management of diabetic macular edema has undergone a paradigm change.<sup>1</sup> This is attributed to the newer diagnostic tests and pharmacological agents. There are enough good randomized controlled trials to prove the efficacy of these drugs. However, in clinical practice, there are many situations where the application of the findings of these clinical trials is often difficult. The aim of this article is to have a consensus statement on initial workup, diagnosis and management of diabetic macular edema.

### Initial assessment of diabetic macular edema

#### History

- History regarding duration of diabetes, past glycemic control (hemoglobin A1c), Medications (especially insulin, oral hypoglycemics, antihypertensives, and lipid-lowering drugs), systemic history (e.g., renal disease, cardiovascular events, systemic hypertension, serum lipid levels, pregnancy).
- History related to drugs causing macular edema (Thiazolidinediones, fingolimod (used in MS), tamoxifen, taxanes, niacin, interferons and prostaglandin analogs).<sup>2-8</sup>

#### Ocular examination

- Detailed patient assessment should include a complete ophthalmic examination, including visual acuity (preferably by a ETDRS/Log MAR chart) and the identification and grading of severity of DR and presence of DME for each eye.<sup>9</sup>

#### Investigations

##### OCT

- All patients with DME should undergo OCT (Both Raster and radial scans). Retinal thickening (Central subfield and inner ETDRS ring thickness measurement), presence of vitreomacular adhesion or traction and morphological features like presence of neurosensory detachment, cystic spaces, foveal contour should be noted.
- The features suggestive of prognosis-like horizontal and vertical extent of IS-OS disruption, ELM disruption and hyper reflective foci (HFs) within the neurosensory retina should be noted. However, in presence of gross cystoid

macular edema, often it is difficult to assess these features.<sup>10</sup>

#### Fundus fluorescein angiography

- Desirable to have baseline FFA done in all cases with DME. If otherwise contraindicated, at least a baseline fundus photo (ETDRS 7 Field) should be done.
- Preferably in cases where vision loss is disproportional to clinical picture (ischemic maculopathy), in cases where there is a suspicion of neovascularization, in cases of mixed retinopathy and those who are non-responders to treatment.
- Avoided in pregnancy, patients with history of serious adverse events during previous FFA and patients with allergy to fluorescein and severely impaired renal function.

#### Systemic

- Monitor fasting and post-prandial sugars, past glycemic control (hemoglobin A1c), Blood pressure and lipid profile (preferable in patient presenting with extensive exudates at macula) anemia and Renal function tests (Blood urea creatinine and microalbuminuria/albuminuria).<sup>11,12</sup>
- Either access the patients recent records/ask the patient to get these tests done and show to his treating physician/or order the investigations and then appropriately refer to physician.

#### Center-involving and non-center involving diabetic macular edema

Assessment: clinically by Slit lamp biomicroscopy and by SD-OCT

##### Center involving DME

*Clinically:* On clinical examination, definite retinal thickening due to diabetic macular edema involving the center of the macula.

##### On SD-OCT

- Loss of foveal contour
- Cystic space involving center of fovea.
- Neurosensory detachment involving the center of fovea
- Retinal thickening on SD OCT: central subfield thickness on OCT  $\geq 290$   $\mu\text{m}$  for women,  $\geq 305$

$\mu\text{m}$  in men on spectral domain OCT (Zeiss cirrus). Heidelberg spectralis:  $\geq 305 \mu\text{m}$  in women, and  $\geq 320 \mu\text{m}$  in men.<sup>13</sup>

Must check the accuracy of OCT scan by ensuring it is centered and of adequate quality (for Zeiss Stratus, standard deviation of center point thickness should be  $\leq 10\%$  of the center point thickness and signal strength should be  $\geq 6$ ).

#### *Non-center involving DME*

*Clinically:* On clinical examination, definite retinal thickening due to diabetic macular edema within  $3,000 \mu\text{m}$  of the center of the macula but not involving the center of the macula.

#### *On SD-OCT*

Cystic spaces and/or retinal thickening in non-central macular subfields

#### *Center and non-center involvement in CSME*

CSME is a form of DME that was precisely defined by the ETDRS as any of the following criteria being met<sup>14</sup>:

- 1 Any retinal thickening within  $500 \mu\text{m}$  of the center of the macula.
- 2 The presence of hard exudates at or within  $500 \mu\text{m}$  of the center of the macula, if associated with thickening of the adjacent retina (not residual hard exudates remaining after the disappearance of retinal thickening)
- 3 A zone, or zones, of retinal thickening 1 disk area or larger, any part of which is within 1 disk diameter (1 disc =  $1500 \mu\text{m}$ ) of the center of the macula.

Criterion 1: Center involving; Criterion 2 and 3: non-center involving

#### **Management of Diabetic macular edema**

##### ***Situation 1: Non-center involving macular edema***

Laser according to the ETDRS guidelines<sup>14,15</sup>:

- Focal photocoagulation: treatment of individual microaneurysms that fill with fluorescein and/or leak, as well as other points of leakage such as intraretinal microvascular abnormalities.
- Optional: treatment of microaneurysms (or punctate hemorrhages)  $< 125 \mu\text{m}$  in longest diameter that did not fill with fluorescein; leaks within hemorrhages; treatment of microaneurysms or other focal points of leakage in the retina further than 2 DD from the center of the macula.
- Avoid: treatment of nerve fiber layer retinal hemorrhage (flame or splinter hemorrhage) and blot hemorrhage  $> 125 \mu\text{m}$  in size.

- *Grid laser treatment* of areas of thickened retina showing diffuse fluorescein leakage and/or capillary dropout.

##### ***Situation 2: Non-center involving macular edema with few cystic spaces involving fovea (minimal center involvement)***<sup>16</sup>

- If the vision is compromised, intravitreal anti-VEGF can be the treatment of choice
- If good vision (6/6), asymptomatic: laser according to the ETDRS guidelines
- If symptomatic and vision is good (6/6): intravitreal anti-VEGF

##### ***Situation 3: Center involving macular edema converting to non-center involving macular edema after intravitreal injections***

- During monthly follow-up after anti-VEGF treatment the visit in which the edema becomes non-center involving, laser according to the ETDRS guidelines can be done. However, the follow-up visits after anti-VEGF injections should be continued as usual.

##### ***Situation 4: predominantly non-center involving macular edema (ring of circinates) after intravitreal injections or laser with plaque of hard exudate and normal foveal contour***

- Control of systemic status (serum lipids), referral to physician to initiate lipid lowering drugs. Intravitreal steroids (1st Choice) can be considered after assessing the risk (Glaucoma). Laser may aggravate subfoveal deposits and should be avoided.<sup>17</sup>

##### ***Situation 5: treatment naïve center-involving macular edema***

Anti-VEGF therapy is the first line of treatment for all DME patients without traction but with central involving macular edema. On monthly follow-up, look for Visual acuity and OCT for improvement.

- OCT and/or vision shows improvement: continue the treatment with anti-VEGF
- OCT shows progressive improvement but vision not improving: continue anti-VEGF, but consider angiogram to look for ischemia at 3 months.
- Vision improving but no OCT improvement: continue the treatment with anti-VEGF. Can consider adding laser, also look for VMA.
- No improvement on OCT and no visual gain: At 3 months, consider angiogram and then plan rescue treatment. Either switch to other

anti-VEGF agent or consider steroid or consider adding laser.

When to stop injections<sup>18</sup>:

- 'Success'; vision improved to 6/6 and on OCT, return to normal foveal contour with reversal of thickening, disappearance of cystic spaces and NSD.
- 'No further improvement' Defined as <10% decrease in central subfield thickness and <5 letter increase in visual acuity since the most recent injection and, in the opinion of the treating ophthalmologist, it seems unlikely that additional treatment would provide any further benefit.

Once injections are stopped, close monitoring (at least every 3 months) with either an as-needed or a 'treat and extend' treatment approach should be done.

Retreatment should be considered in any case that involves significant fluid reappearance. However, clinical judgment is required.

When to switch to other agents

Patients with progressive worsening of vision over three consecutive visits in the presence of active DME (i.e., when other causes of vision loss have been excluded) can be considered as non-responders.

**Situation 6: Previously treated center—involving macular edema with multiple Anti-VEGF injections/Steroid injections/laser**

- Stable: Control of systemic factors and follow-up based on time of last injection.
- Resistant: Evaluate with FFA and OCT.
  - ✓ Identify the ETDRS treatable lesions (retinal microaneurysms located between 500 and 3000  $\mu\text{m}$  from the foveal center, retinal microaneurysms located between 300 and 500  $\mu\text{m}$  from the foveal center causing persistent CSME despite first laser treatment, areas of diffuse retinal leakage that could arise from microaneurysms, dilated capillary bed or intraretinal microvascular abnormalities and thickened ischemic zones) and treat if present.
  - ✓ Carefully evaluate the follow-up protocols and response of previous treatments. Try to find out which treatment had the best response. Initiate the treatment with the same pharmacological agent and follow-up closely.
  - ✓ Evaluate the systemic control of Diabetes, lipids, hypertension. Assess the renal status. Refer to a physician for adequate control.
- Recurrent: evaluate with FFA and OCT. Treat according to center involvement. Treat with drug which had shown good response

previously. Evaluate the systemic factors for recurrence.

**Situation 7: Proliferative diabetic retinopathy with macular edema**

- If no traction: complete Pan retinal photocoagulation along with anti-VEGF and then subsequent management of macular edema according to the protocol.
- In presence of vitreous hemorrhage with hazy view of retina with suspected diabetic macular edema: PRP to the extent possible and pharmacological agents.
- In the presence of extramacular traction: PRP with burns 2 DD away from TRD, macular edema can be treated as usual protocol.
- In the presence of traction threatening or involving fovea: vitrectomy is indicated.

**Situation 8: center involving macular edema with vitreoretinal surface abnormalities**

- Evaluate the vitreoretinal interface on OCT.
- Focal vitreomacular traction with macular edema: vitrectomy is the choice.
- Extrafoveal traction site(s) without traction at the vitreofoveal site: anti-VEGF treatment can be initiated, with a close watch at the extrafoveal traction site on follow-up. However, if the traction is significant, option of IVTA/Ozurdex can be considered.
- Broad adherent epiretinal membrane with retinal thickening (VMA): in presence of changes due to diabetic macular edema, cystic spaces, NSD, retinal thickening, diffuse leak on FFA: treat like center involving macular edema. However, these show a relatively poor response to pharmacological treatment.
- Broad adherent epiretinal membrane with retinal thickening with no associated DME changes as mentioned above and thickening attributable to ERM: If asymptomatic; needs observation with OCT on follow-up visits. However, if symptomatic and shows worsening on follow-up visits (drop in vision) can plan vitrectomy with epiretinal membrane removal. If planning vitrectomy the prognostic features which should be taken into account include initial visual acuity (poorer VA has poor prognosis), OCT features like IS-OS defects and breaks in ELM, FFA features like the presence of ischemia, and status of optic nerve (pallor).

**Situation 9: Center involving macular edema in pseudophakic eyes**

- *Differentiating pseudophakic from Diabetic macular edema in presence of DR:* diffuse petalloid type of leakage with disc leakage on the fluorescein angiogram and with very few aneurysms and no hard exudates around the macula is suggestive of pseudophakic macular edema.
- *Presence of diabetic macular edema with no component of Irvine Gass:* treat as center involving macular edema. However, if compliance is an issue one can initiate the treatment with intravitreal steroids.
- *Presence of both diabetic macular edema and Irvine Gass:* can plan treatment of diabetic macular edema along with non-steroidal anti-inflammatory drugs. If no contraindications, intravitreal steroids can be considered as an initial choice.
- *Time to start treatment of DR in fresh pseudophakia:* if macular edema is detected after cataract surgery, laser (macular) can be initiated after 1 month (after uncomplicated phacoemulsification); PRP if indicated can be done early (with indirect laser delivery or gentle slit lamp delivery after sterilizing the contact lens) and intravitreal anti-VEGF can also be planned after 1 month.

**Situation 10: Macular edema during pregnancy<sup>19</sup>**

- Pregnancy may promote the onset of DR (in about 10% of cases) as well as contribute to its worsening when already present.
- The proliferative retinopathy must always be treated; treatment should be earlier in pregnant women compared to non-pregnant women.
- Pregnancy can also cause macular edema; it spontaneously regresses during postpartum and therefore does not require immediate treatment.
- However, if macular edema occurs early in the pregnancy and there is progressive deterioration of vision, laser/intravitreal steroids should be preferred and anti-VEGF avoided.

**Situation 11: macular edema in young type 1 diabetes**

- Management of DME in type 1 diabetes is similar to type 2; however, they need to be referred to their physician for optimal glycemic control.
- In cases of PDR with macular edema, there is an increased risk of thickened PHF

contributing to edema. Clinical and OCT assessment of this is important.

**Situation 12: center involving macular edema in vitrectomized eyes**

- Pseudophakic eyes with center involving macular edema: intravitreal steroids should be considered as first choice in suitable cases.<sup>20</sup>
- In presence of recurrent vitreous hemorrhage with center involving macular edema: anti-VEGF are the better choice.
- Selected cases where the risk of IOP spike and cataract is a concern: intravitreal anti-VEGF can be considered. Close monitoring of IOP and counseling of patient is important. Consider choosing dexamethasone over IVTA to reduce IOP spikes.

**Situation 13: ischemic macular edema**

- Access the ischemia with FFA and OCT
  - FFA: the minimum criterion for diagnosing macular ischemia is moderate FAZ irregularities.<sup>21</sup>
    - Moderate irregularities is defined as abnormally dilated and tortuous capillaries budding into the FAZ, terminal arterioles/venules directly abutting FAZ margins, and enlarged intercapillary spaces around the FAZ. The size is a minor criterion compared to the irregularity of FAZ. Ischemia was diagnosed only when the longest diameter of FAZ was  $\geq 1000 \mu$  (the measurements should be made digitally using a FF 450plus fundus camera [VISUPAC system, Carl Zeiss, Germany]).
    - Severe FAZ irregularity is defined as the destruction of the FAZ architecture: grossly enlarged FAZ with 'pruned off' arterioles.
    - Normal FAZ is defined as an FAZ  $<1000 \mu$  in the longest diameter, regular and round/horizontally oval in shape. Mild undulations of FAZ were also considered normal.
- Can also grade ischemia using ETDRS grading system,<sup>22</sup> from 0 (normal), to 1 (questionable), 2 (less than half the original circumference destroyed), 3 (more than half the contour destroyed but some remnants remain), and 4 (capillary outline completely destroyed).
- Assessing ischemia on OCT: DME in presence of ischemia has retinal thickening in the outer retinal layers. Inner retinal layers, including the ganglion cell layer (GCL) and RNFL, are thinned.
- In FFA grade 1 and 2: treat as non-ischemic (Center and non-center involving)



- FFA Grade 3: avoid laser photocoagulation, can consider steroids in the presence of center involving macular edema
- FFA Grade 4: would not benefit from any treatment.

**Situation 14: center involving macular edema with history of recent stroke**

- If a patient had stroke (cerebrovascular accidents) or myocardial infarction, within last 3 months, do not initiate treatment with anti-VEGF. Treatment with laser or steroids can be considered in these patients.
- If the history is >3 months old, the treatment can be initiated with anti-VEGF. However, if systemic risks of thromboembolic phenomenon are significant, it is best to consult a physician first.

**Situation 15: diabetic macular edema in glaucomatous eyes**

- In eyes with established glaucoma/glaucoma suspect/ocular hypertension: avoid intravitreal steroids. Even if intravitreal anti-VEGFs are used, monitoring of IOP and if required augmentation of anti-glaucoma medications is required.
- For rescue treatment in this group, laser photocoagulation is preferred.

**Situation 16: considering diabetic macular edema for vitrectomy**

- Focal vitreomacular traction: vitrectomy is the choice.
- Broad vitreoretinal adhesion: if anti-VEGFs and rescue treatment have failed to resolve the macular edema and the ophthalmologist feels that there is a scope of improvement, vitrectomy can be considered.
- Diffuse diabetic macular edema: if does not show desired outcome after primary and rescue treatment, can be considered for vitrectomy with or without ILM peeling. Patients vision, optic disc status, and macular perfusion need to be evaluated first.

**Situation 17: Cataract with Diabetic macular edema**

- Diabetic macular edema with cataract: as long as there is a clear enough view to see DME clinically and on OCT treat DME according to the protocol. Once macular edema is treated, one can plan cataract surgery. Ideally we can wait for 3 months after cataract surgery.

- However, if the view is not good enough to treat DME, cataract surgery can be done either along with intravitreal anti-VEGFs, or 2 weeks after surgery and subsequent protocol continued.

- If the view is clear and treatment initiated, but even after three to four injections, the edema has not resolved; and during this time cataract has worsened: cataract surgery can be planned and treatment of DME continued thereafter. Can consider concurrent intravitreal injection or injection post-surgery based on logistics.
- If during treatment of DME, patient also develops PCO, NdYAG capsulotomy can be planned and treatment of DME can be continued as usual.

**Situation 18: diabetic macular edema with optic nerve abnormalities**

Differentiating NA-AION, papillopathy and papillophlebitis:

- NA-AION: the optic disc edema in NAION may be diffuse or segmental, hyperemic or pale, but pallor occurs less frequently than it does in AAION. A focal region of more severe swelling often is seen and typically displays an altitudinal distribution, but it does not correlate consistently with the sector of visual field loss. Diffuse or focal telangiectasia of the edematous disc may be present, occasionally prominent enough to resemble a vascular mass or neovascularization.
- Papillopathy: acute onset of unilateral or bilateral disc edema in usually in young, type 1 diabetics, sometimes even type 2 diabetes, without the usual defects in visual field and pupillary function associated with NAION or optic neuritis.
- Papillophlebitis: typically shows more prominent retinal venous congestion, peripheral retinal hemorrhages.
- In AION cases, FFA shows early disc hypofluorescence due to hypoperfusion with late leakage around the affected segment. However, in diabetic papillopathy cases the FFA shows a very early disc leakage that increases throughout the study. The early hyperfluorescence is most likely due to telangiectasia of the optic disc. Fields typically show altitudinal defect in NA-AION which are not seen in papillopathy.

NA-AION with macular edema: differentiate whether the macular edema is due to Macular star seen in NA-AION or diabetic macular edema. FFA plays an important role. Identify the presence of DR lesions which can cause edema (MA, diffuse leak, IRMA). If it is due to diabetic macular

edema, treat as either center involving or non-center involving. If it is due to NA-AION, treatment of NA-AION would resolve the edema, no treatment by intravitreal injections is required.

Papillopathy with diabetic macular edema: treat the macular edema as any other diabetic macular edema.

Papillophlebitis with macular edema: FFA to determine whether the macular edema is due to diabetes or vein occlusion. If due to diabetes, treat as any other diabetic macular edema. In these cases, one should rule out inflammatory causes as well.

#### **Situation 19: diabetic macular edema with anemia**

- In the majority of patients, the anemia is related to renal dysfunction and may require subcutaneous erythropoietin injections for treatment. The macular edema usually improves with it; however, one should keep a close watch on proliferative component, as erythropoietin can worsen the same.
- Anti-VEGF can be the preferred agent in presence of anemia and center involving DME.

#### **Situation 20: diabetic macular edema with mixed retinopathy**

- The management of diabetic macular edema remains unchanged; however, the history of cardiovascular risk factors should be sought and if required a physician consultation should be done.
- In cases of accelerated hypertension, anti-VEGF should be avoided.

#### **Situation 21: Diabetic macular edema with lattice degenerations**

A careful examination of the periphery, and prophylactic treatment of any lesions that could predispose to RD, is preferable. The gap between laser prophylaxis and the injection should ideally be 3 weeks.

#### **Challenges in any intravitreal injection among diabetics**

**Need for bilateral injection:** On many occasions there is a requirement of multiple Anti-VEGF injections in both eyes. Ideally a gap of a week or at least 3 days should be kept between both the eyes.

**Patient with non-healing foot ulcer:** This poses a risk of infection. Before injections make it sure the patient is in care of a surgeon/physician. The attendant and patient should be counseled to do foot dressing before doing ocular dressing or instilling the drops. In presence of active infection,

intravitreal injections should be avoided. Look for non-invasive alternatives such as laser if feasible.

**Fluctuating glycemic control:** These patients pose a challenge for the treating physician, as before each anti-VEGF injection, the blood sugar has to be <200 mg%; fluctuating glycemic control can alter the compliance of regular intravitreal injections.

**Monthly follow-up:** As diabetics, often also have other co-morbid conditions which require regular care like nephropathy, cardiovascular problems, neuropathy etc.; regular monthly follow-up may not be feasible in some of them. If compliance is an issue, laser treatment can be considered.

## **Conclusion**

Management of diabetic macular edema is a challenging situation; as in clinical practice we come across many combinations of phenotypes and clinical scenario. The choice and protocols of management may slightly differ; however, principles of treatment remain same. The clinical trials in the last decade with pharmacotherapy have largely helped in changing paradigms in management of DME.

## **References**

1. Arevalo JF. Diabetic macular edema: changing treatment paradigms. *Curr Opin Ophthalmol.* 2014;25(6):502-7.
2. Idris I, Warren G, Donnelly R. Association between thiazolidinedione treatment and risk of macular edema among patients with type 2 diabetes. *Arch Intern Med.* 2012;172(13):1005-11.
3. Nieraj J, Tariq Bhatti M. Fingolimod-associated macular edema. *Neurology.* 2012;78(9):672-80.
4. Nayfield SG, Gorin MB. Tamoxifen-associated eye disease. A review. *J Clin Oncol.* 1996;14(3):1018-26.
5. Modi D, Dubovy SR. Non-leaking cystoid maculopathy secondary to systemic paclitaxel. *Ophthalmic Surg Lasers Imaging Retina.* 2013;44(2):183-6.
6. Trechot P, Conart JB, Trechot F, Petitpain N, Angioi K, Berrod JP. Pathophysiological hypothesis regarding the role of nicotinamide in the genesis of niacin-induced macular edema. *J Fr Ophthalmol.* 2014;37(4):e49-51.
7. Sheth HG, Michaelides M, Siriwardena D. Cystoid macular edema and visual loss as sequelae of interferon alpha treatment of systemic hepatitis C. *Indian J Ophthalmol.* 2010;58(2):147-8.
8. Brasil OF, Brasil MV, Ventura MP, Maia HS. Bilateral and simultaneous cystoid macular edema associated with latanoprost use: report of two cases. *Arq Bras Oftalmol.* 2010;73(2):186-8.
9. Beck RW, Moke PS, Turpin AH, Ferris FL III, SanGiovanni JP, Johnson CA, Birch EE, Chandler DL, Cox TA, Blair RC, Kraker RT. A computerized method of visual acuity testing: adaptation of the early treatment of diabetic retinopathy study testing protocol. *Am J Ophthalmol.* 2003;135:194-205.
10. Bolz M, Schmidt-Erfurth U, Deak G, Mylonas G, Kriechbaum K, Scholda C; Diabetic Retinopathy Research Group Vienna. Optical coherence tomographic hyperreflective foci: a morphologic sign of lipid extravasation in diabetic macular edema. *Ophthalmology.* 2009;116(5):914-20.
11. Wan Nazaimoon WM, Letchuman R, Noraini N, Ropilah AR, Zainal M, Ismail IS, Wan Mohamad WB, Faridah I, Singaraveloo M, Sheriff IH, Khalid BA. Systolic hypertension and duration of diabetes mellitus are important determinants of

- retinopathy and microalbuminuria in young diabetics. *Diabetes Res Clin Pract.* 1999;46:213–21.
12. Gaede P, Vedel P, Parving HH, Pedersen O. Intensified multifactorial intervention in patients with type 2 diabetes mellitus and microalbuminuria: the Steno type 2 randomised study. *Lancet.* 1999;353:617–22.
  13. Bressler NM, Edwards AR, Antoszyk AN, Beck RW, Browning DJ, Ciardella AP, Danis RP, Elman MJ, Friedman SM, Glassman AR, Gross JG, Li HK, Murtha TJ, Stone TW, Sun JK, Diabetic Retinopathy Clinical Research Network. Retinal thickness on Stratus optical coherence tomography in people with diabetes and minimal or no diabetic retinopathy. *Am J Ophthalmol.* 2008;145:894–901.
  14. Early Treatment Diabetic Retinopathy Study Research Group. Photocoagulation for diabetic macular edema. Early Treatment Diabetic Retinopathy Study report number 1. *Arch Ophthalmol.* 1985;103:1796–806.
  15. Early Treatment Diabetic Retinopathy Study design and baseline patient characteristics. *ETDRS Report Number 7. Ophthalmology* 1991;98:741–56.
  16. Elman MJ, Aiello LP, Beck RW, Bressler NM, Bressler SB, Edwards AR, Ferris FL III, Friedman SM, Glassman AR, Miller KM, Scott IU, Stockdale CR, Sun JK. Randomized trial evaluating ranibizumab plus prompt or deferred laser or triamcinolone plus prompt laser for diabetic macular edema. *Ophthalmology.* 2010;117:1064–77 e35.
  17. Cekiç O, Bardak Y, Tiğ US, Yildizoglu U, Bardak H. Quantitative evaluation of reduction of plaque-like hard exudates in diabetic macular edema after intravitreal triamcinolone injection. *Int Ophthalmol.* 2008;28(2):95–9.
  18. Aiello LP, Beck RW, Bressler NM, Browning DJ, Chalam KV, Davis M, Ferris FL III, Glassman AR, Maturi RK, Stockdale CR, Topping TM. Rationale for the diabetic retinopathy clinical research network treatment protocol for center-involved diabetic macular edema. *Ophthalmology.* 2011;118(12):e5–14. doi:10.1016/j.ophtha.2011.09.058.
  19. Sinclair SH, Nesler C, Foxman B, Nichols CW, Gabbe S. Macular edema and pregnancy in insulin-dependent diabetes. *Am J Ophthalmol.* 1984;97(2):154–67.
  20. Yanyali A, Aytug B, Horozoglu F, Nohutcu AF. Bevacizumab (Avastin) for diabetic macular edema in previously vitrectomized eyes. *Am J Ophthalmol.* 2007;144(1):124–6.
  21. Shukla D1, Kolluru CM, Singh J, John RK, Soman M, Gandhi B, Kim R, Perumalsamy N. Macular ischaemia as a marker for nephropathy in diabetic retinopathy. *Indian J Ophthalmol.* 2004;52(3):205–10.
  22. Sim DA1, Keane PA, Fung S, Karampelas M, Sadda SR, Fruttiger M, Patel PJ, Tufail A, Egan CA. Quantitative analysis of diabetic macular ischemia using optical coherence tomography. *Invest Ophthalmol Vis Sci.* 2014; 55(1):417–23.

**How to cite this article** Raman R, Bhende M. Diabetic Macular Edema, *Sci J Med & Vis Res Foun* 2015;XXXIII:50–56.

# Micro Incision Vitrectomy Surgery (MIVS): An Overview

Pramod S. Bhende and Aneesha Lobo

Sri Bhagwan Mahavir  
Vitreoretinal Services,  
Sankara Nethralaya

## Correspondence to:

Pramod S Bhende,  
Deputy Director and Senior  
Consultant,  
Sri Bhagwan Mahavir  
Vitreoretinal Services,  
Sankara Nethralaya.  
E-mail: drpb@snmail.org

## Introduction

In today's world of nano-technology where bigger no longer means better, everything from smart-phones to surgical incisions are getting smaller and more refined. The advantages of smaller surgical incision have resulted in faster postoperative recovery.

Vitreoretinal surgery is no exception. We have come a long way since the time of open sky vitrectomy and Machemer's first 17-gauge closed pars plana vitrectomy (PPV) in 1971.<sup>1</sup> In 1974, O'Malley and Heintz<sup>2</sup> introduced a smaller 20-gauge (G) vitrector (0.9 mm diameter) for use with the three-port sclerotomy system that became the gold standard for modern PPV and has been the standard of care for almost three decades.

However, in current times, just attaching the retina is not enough. Variables like patient comfort (both intra and post-operative), surgical time and precision, post-operative recovery time, surgically induced refractive error, cosmesis, etc. are becoming increasingly important. To take these factors into account, 'Transconjunctival sutureless vitrectomy' (TSV), subsequently renamed and popularly known as microincision vitrectomy system (MIVS) has come about. The 25-gauge vitrectomy was introduced<sup>3</sup> in 2002 by Fujii *et al* followed by the 23 gauge in 2005 by Eckardt<sup>4</sup> and Stanley Chang which combined the benefits of 20 and 25 gauge. In 2010, Oshima introduced even smaller, 27-gauge instrumentation.<sup>5</sup>

As a result of these advances, vitreoretinal surgeons now have multiple choices when determining their operative approach. In this article, we would like to give a brief overview of the various MIVS systems available.

## Instrumentation

In MIVS, three micro-cannulas are inserted in the pars plana (with the help of insertion trocar) through the conjunctiva and sclera through a two-step incision. The infusion line and vitreoretinal instruments are then introduced into the vitreous cavity through these cannulas. At the end of the procedure, the cannulas are removed without suturing either the sclera or the conjunctiva.

The inner diameters of the 25- and 23-gauge cannulas are 0.57 and 0.65 mm, respectively,<sup>3,4</sup> in contrast to the 0.9 mm diameter of a conventional 20-gauge incision while that of the 27-gauge cannula is 0.4 mm.<sup>5</sup> These narrow incisions do not need to be sutured, thus providing minimal surgical trauma and brief recovery times.

In comparison to 20 gauge, the MIVS cutter port is smaller and closer to the tip (Fig. 1). A smaller port and a proximity closer to the tip maybe advantageous when performing complex manoeuvres, such as shaving of the vitreous base, working near detached mobile retina, membrane segmentation or delamination. The MIVS system also comes equipped with higher cutting rates extending up to 5000–8000 cpm; which reduces the likelihood of uncut vitreous fibers going through the cutter port, thereby reducing dynamic vitreoretinal traction with less chance of iatrogenic retinal tears and damage to the retinal surface. To achieve this high cutting rate without vibrations for better stability and precision cutting newer cutters do not have spring to drive the guillotine.

## Rigidity

The main concern while using the smaller gauge instruments is the bending or breakage of the flexible instruments and difficulty in manoeuvring the globe with the help of these flimsy instruments. This problem is more noticeable with the 25- and 27-gauge instruments as compared to 23 gauge. In order to overcome this, second generation instruments, 25+ and 27+, respectively, have been introduced by adding 5 mm supporting sleeve near proximal end to make instruments stiffer and less malleable. However, this reduces the effective working length of the instrument which is disadvantageous while operating on eyes with longer axial lengths. Careful positioning of the sclerotomies can also reduce tool flexion.

## Illumination

Reducing the diameter of a light pipe by 20% theoretically reduces the amount of illumination by ~35%. The conventional illumination (halogen) used in 20-gauge PPV is not adequate for MIVS. Currently, with the new-generation xenon and mercury vapor illumination sources, illumination inside the vitreous cavity has greatly improved. When combined with chandelier illuminators or multifunction instruments, these sources have made bimanual microincision vitrectomy a reality.

## Aspiration and flow rates


In accordance to the Poiseuille's law, which states that the flow through a tube is proportional to the fourth power of the radius of the tube, it is evident that even a minor reduction in the inner diameter of the tubing will result in a significant reduction in the flow across the tube. As a result



**Fig. 1.** 23G cutter port is closer to tip compared to 20G cutter



**Fig. 2.** Dual actuation lines (ALCON) allows duty cycle control, to make cutting more effective



**Fig. 3.** Comparison between B&L and Alcon 25 gauge probe

of different flow characteristics imparted by a reduction in the size of the opening of small-gauge vitreous cutters, higher infusion and aspiration rates are necessary to optimize flow and vitreous removal. Higher aspiration flow rates will reduce the surgical time but at the cost of risking inadvertent breaks and retinal engagement in the cutter port, especially when working in the periphery or with detached retina. 'Aspiration flow limit' is a feature complimentary to variable duty cycle and high cut rate in newer machines and once set, it maintains continuous state of fluidic stability in the eye, preventing sudden decrease in intraocular pressure and pulsatile traction on the retina.

## Complications

### Wound leakage

Post-operative wound leak has always been a concern with MIVS.<sup>6</sup> These issues can be addressed by proper wound construction. Displacement of the conjunctiva before entry so that the conjunctival and scleral incisions are misaligned has found to reduce wound leakage. Oblique/angled entry has less incidence of wound leakage as compared to perpendicular entry and biplanar incisions are advantageous over uniplanar ones.

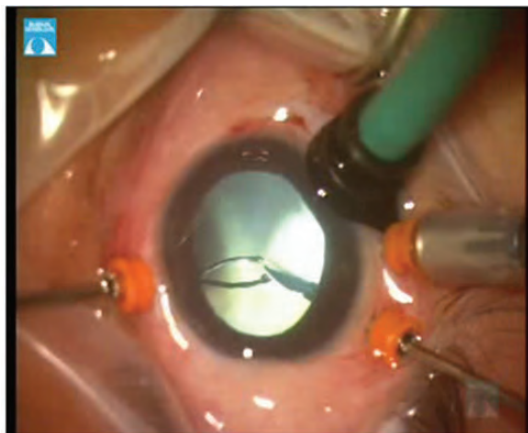


Fig. 4. Four-port vitrectomy for ROP using MIVS

Previous vitrectomy contributed to wound leakage in 23-gauge vitrectomy in a study conducted by Woo et al.<sup>7</sup> Previous sclerotomy sites are structurally weaker because of scarring and fibrosis and reduced rigidity of the sclera could increase the likelihood of wound leakage. A clinical study<sup>8</sup> using 25-gauge MIVS did correlate younger age as a contributing factor for early postoperative hypotony. Gupta et al.<sup>9</sup> found post-operative day 1 intraocular pressure to be statistically lower than preoperative pressures, when eyes were left fluid filled. This was not the case in air or gas filled eyes.

### Post-operative endophthalmitis

Kaiser et al. in their presentation at the 2007 Vail Vitrectomy meeting reported 0.23% incidence of endophthalmitis in 3103 consecutive eyes undergoing MIVS. This is in contrast to only one case of endophthalmitis in 5498 consecutive 20-gauge vitrectomies (an incidence of 0.0018%) performed by the same surgeons, at the same institution, over the same period.<sup>10</sup> However, four other studies (three with level II evidence) that compared rates of acute endophthalmitis between 20- and 25-gauge vitrectomy did not show<sup>(11-14)</sup> a statistically significant difference in incidence of endophthalmitis. In a similar comparative study of 23-gauge and 20-gauge cases, no case of endophthalmitis was observed among 943 eyes after 23-gauge PPV.<sup>15</sup>

### Indications of MIVS

#### 23 Gauge

Though it can be used universally, 23-gauge system is ideally suited for rhegmatogenous retinal detachment surgery and for diabetic vitrectomies. It can also be used in cases of endophthalmitis and trauma especially foreign body removal.

#### 25 and 27 Gauge

They are more suitable for macular surgery (Macular hole/macular pucker/epiretinal membrane) and simple cases of vitreous hemorrhage.

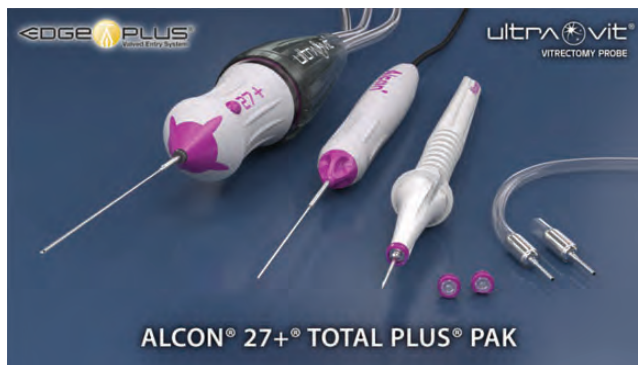

Fig. 5. Alcon 27 gauge vitrectomy system

Branch vein decompression (sheathotomy) can also be performed. 25G instruments are also preferred in pediatric cases.

#### *Advantages of MIVS over conventional 20 gauge*

- Sutureless procedure: so better patient comfort.
- Less inflammation: faster healing and recovery of visual acuity.
- Less surgery induced refractive error.
- Reduced conjunctival scarring: Useful for patients requiring multiple surgeries and also prior to or anticipated glaucoma filtering surgeries or candidates with ocular surface disorders.
- Port design helps in more complete vitrectomy and easier dissection of proliferative membranes.
- Higher cut rates and smaller port aperture reduces the chances of inadvertent retinal breaks.

#### *Disadvantages of MIVS when compared to 20 gauge*

- Actual time for performing vitrectomy may be longer
- Not suitable for cases where extensive dissection is needed and in eyes where fragmatome have to be used
- Higher infusion pressure may cause optic nerve damage
- Smaller incision may limit the maximum flow across the port
- Flimsy instruments which may deform or break during surgery
- With long trocar blade, there is an increased risk of retinal injury in eyes with anteriorly displaced retina
- Increased risk of post-operative hypotony, choroidal detachments and endophthalmitis due to gaping wounds

### **Conclusion**

The development of MIVS has provided surgeons with new options in the surgical treatment of

vitreoretinal diseases. Each system has its advantages and disadvantages. The optimum gauge and settings have to be selected after careful deliberation to provide the best possible surgical outcome.

### **References**

1. Macheimer R, Parel JM, Norton EW. Vitrectomy: a pars plana approach. Technical improvements and further results. *Trans Am Acad Ophthalmol Otolaryngol.* 1972;76:462-6.
2. O'Malley C, Heintz RM Sr. Vitrectomy with an alternative instrument system. *Ann Ophthalmol.* 1975;7:585-88; 91-94.
3. Fujii GY, De Juan E Jr, Humayun MS, et al A new 25-gauge instrument system for transconjunctival sutureless vitrectomy surgery. *Ophthalmology.* 2002;109:1807-12; discussion 13.
4. Eckardt C. Transconjunctival sutureless 23-gauge vitrectomy. *Retina.* 2005;25:208-11.
5. Oshima Y, Wakabayashi T, Sato T, et al A 27-gauge instrument system for transconjunctival sutureless microincision vitrectomy surgery. *Ophthalmology.* 2010;117:93-102.
6. Lakhnani RR, Humayun MS, Juan E Jr, et al Outcomes of 140 consecutive cases of 25-gauge transconjunctival surgery for posterior segment disease. *Ophthalmology.* 2005;112:817-24.
7. Woo SJ, Park KH, Hwang J, Kim JH, Yu YS, Chung H. Risk factors associated with sclerotomy leakage and postoperative hypotony after 23-gauge transconjunctival sutureless vitrectomy. *Retina.* 2009;29:456-63.
8. Byeon SH, Lew YJ, Kim M, Kwon OW. Wound leakage and hypotony after 25-gauge sutureless vitrectomy: factors affecting postoperative intraocular pressure. *Ophthalmic Surg Lasers Imaging.* 2008;39:94-9.
9. Gupta OP, Weichel ED, Regillo CD, et al Postoperative complications associated with 25-gauge pars planavitrectomy. *Ophthalmic Surg Lasers Imaging.* 2007;38:270-5.
10. Hilel Lewis. Sutureless microincision vitrectomy surgery: unclear benefit, uncertain safety (Editorial). *Am J Ophthalmol.* 2007;Oct:613-15.
11. Hu AY, Bourges JL, Shah SP, et al Endophthalmitis after pars planavitrectomy: a 20- and 25-gauge comparison. *Ophthalmology.* 2009;116:1360-65.
12. Mason JO III, Yunker JJ, Vail RS, et al Incidence of endophthalmitis following 20-gauge and 25-gauge vitrectomy. *Retina.* 2008;28:1352-54.
13. Shimada H, Nakashizuka H, Hattori T, et al Incidence of endophthalmitis after 20- and 25-gauge vitrectomy: causes and prevention. *Ophthalmology.* 2008;115:2215-20.
14. Chen JK, Khurana RN, Nguyen QD, Do DV. The incidence of endophthalmitis following transconjunctival sutureless 25- vs 20-gauge vitrectomy. *Eye.* 2009;23:780-4.
15. Parolini B, Romanelli F, Prigione G, Pertile G. Incidence of endophthalmitis in a large series of 23-gauge and 20-gauge transconjunctival pars planavitrectomy. *Graefes Arch Clin Exp Ophthalmol.* 2009;247:895-8.

**How to cite this article** Bhende P.S., Lobo A. Micro Incision Vitrectomy Surgery (MIVS): An Overview, *Sci J Med & Vis Res Foun* 2015;XXXIII:57-60.

The authors have no commercial associations that may pose a conflict of interests in connection with this article.

# Endophthalmitis: Current Trends, Drugs and Protocols

Aditya Verma, Vinata Muralidharan and Eesh Nigam

Shri Bhagwan Mahavir  
Vitreoretinal Services,  
Sankara Nethralaya

**Correspondence to**  
Aditya Verma,  
Consultant,  
Shri Bhagwan Mahavir  
Vitreoretinal Services,  
Sankara Nethralaya.  
Email: drav@snmail.org

A brief summary of management of endophthalmitis is being highlighted with pertinent information regarding the relevant and most commonly used antibiotics. Endophthalmitis, in any clinical presentation, should be considered as an ophthalmic emergency. Tailored approach to each individual patient is warranted.

**Definition:** Inflammation of intraocular fluids and tissues (Fig. 1), which can be either infectious or sterile.

**Classification (based on etiology):**<sup>1</sup>

- Exogenous (post-operative [most common], traumatic, local spread).
- Endogenous (metastatic): hematogenous spread.
- Non-infectious (sterile uveitis, lens induced/phaco-anaphylactic, sympathetic ophthalmia).

### Nuggets

- The most common etiology of endophthalmitis is post-operative (cataract extraction and bleb related endophthalmitis).<sup>2</sup>
- The acute and fulminant presentations of endophthalmitis should be differentiated from Toxic Anterior Segment Syndrome (TASS).

## Work sheet of a case of infective endophthalmitis

**At presentation**

### 1. History taking (Table 1)

- Inciting event: surgery (cataract/glaucoma/vitreoretina/keratoprosthesis/intravitreal

injections); trauma; endogenous; contiguous spread (corneal ulcer, scleral abscess)

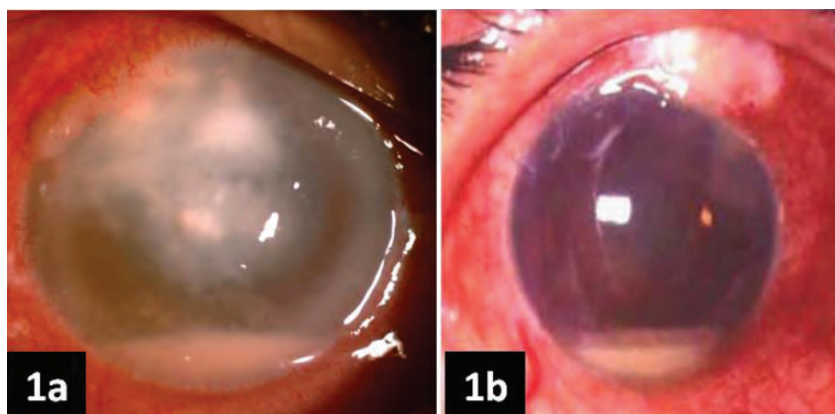
- Onset: acute, sub-acute or chronic
- Progression: rapid or gradual
- Symptoms: decreased vision, pain, redness, floaters, lacrimation, photophobia
- Systemic illness: uncontrolled diabetes, chronic debilitating illness, endocarditis, liver abscess, long-term hospitalization

### Nuggets

The work up of a patient with endophthalmitis should be considered as utmost emergency, since the highly virulent organisms and their toxins can damage the ocular structures within hours.

## 2. Work up

- Initial ophthalmic assessment
  - Initial visual acuity (unaided and with correction, both eyes)
  - Examination of the lids and adnexa
  - Examination of specific areas of interest (filtering bleb, trauma site, cataract wound)
  - Anterior segment examination (with detailed documentation)
  - Intra-ocular pressure (digital/applanation depending upon corneal clarity and integrity)



**Figure 1.** Clinical picture of (a) post-operative endophthalmitis and (b) filtering bleb-related endophthalmitis.



**Table 1:** Classification of post-operative endophthalmitis<sup>1,2</sup>

Type	Features			
	Time of presentation	Commonly implicated organisms	Commonly associated surgical procedure	Presence of hypopyon and pain
Fulminant	<4 days	Gram negative bacteria, <i>Pseudomonas aeruginosa</i> , <i>Streptococcus pneumonia</i> , <i>Staphylococcus aureus</i>	Cataract surgery	Very common
Acute	2–11 days (average 5–7 days)	Coagulase-negative staphylococci, <i>Staphylococcus aureus</i> , streptococcus species, Gram-negative bacteria	Cataract surgery With posterior capsule rupture, vitreous loss Secondary IOL implantation	Very common
Sub-acute/delayed onset	2 weeks–months (average 4–6 weeks)	<i>Propionibacterium acnes</i> , <i>Staphylococcus epidermidis</i> , fungi ( <i>Candida parapsilosis</i> ), <i>Corynebacterium sp.</i>	Cataract surgery With thickened, cheesy posterior capsular thickening	Uncommon  Most common presentation is vision loss
Chronic/late onset	Months–years (Average >6 weeks)	* <i>Streptococcus sp.</i> , Enterococci, <i>Hemophilus influenza</i> , <i>Staphylococcus species</i>  **Fungi	Filtering bleb surgery With anti-fibrotic agents, thin walled, cystic leaking blebs  Cataract surgery	Very common ‘White on red appearance’ (white bleb surrounded by congested conjunctiva <sup>3</sup> )  Uncommon

\*Acute onset presentation.

\*\*Chronic, late onset presentation.

- vi Extra-ocular movements
- vii Detailed fundus evaluation after dilatation with good documentation
- viii Ultrasound B scan if hazy media
- ix Written informed consent for further management
- x Immediate microbiology requisition, informing anesthetist/OR staff (if pediatric/fulminant)
- xi Anterior chamber tap (for initial microbiological evaluation)
- xii Empirical therapy (systemic, intravitreal, topical in combinations)
- xiii Admit and close watch (initially over hours)
- b Check previous medical records and relevant systemic history, inform the patient and relatives about the seriousness of the condition
- c Inform the concerned medical staff (surgeon, nursing staff, operation theatre)
- d Inform the primary surgeon (in case of in-house infection)

**Nuggets**

The most relevant ultrasound findings to be looked for are: amount of exudation, retinal status, choroidal thickness, axial length, and the presence of T sign, retained intra-ocular foreign body or lens matter.

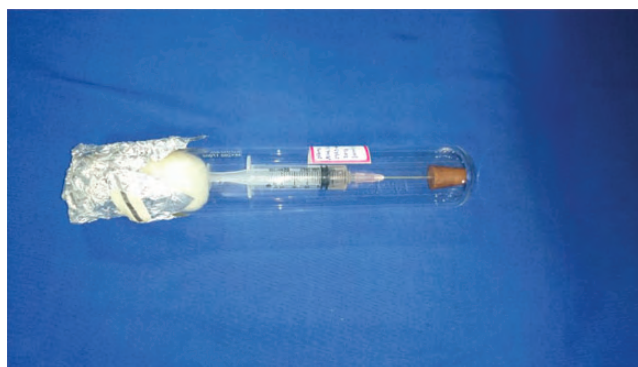**3. Procedure of anterior chamber tap (AC tap)**

a. Requirements (Fig. 2)

- i Microbiology personnel/inoculation media (if done after working hours)
- ii Sterile transport tube with a rubber bunk inside
- iii 1 ml sterile (tuberculin) syringe
- iv 30G sterile needle (27G for thick exudates)
- v Lid speculum
- vi Sterile cotton tip applicators
- vii Protective hand gloves
- viii Lighting source (indirect ophthalmoscope (preferred)/slit lamp)



**Figure 2.** Instruments required for anterior chamber/vitreous tap and intravitreal injections.



**Figure 3.** The sterile test tube container used to transfer the sample (aqueous/vitreous/others) to microbiology laboratory.

- |   |  |
|---|--|
| <ul style="list-style-type: none"> <li>ix Proparacaine, povidone iodine eye drops</li> <li>x Eye patch</li> </ul>   | <ul style="list-style-type: none"> <li>vii Plan the site of tap based on AC depth, visibility, ease of access and the area of maximum exudation.</li> </ul>  |
| <p>b. Procedure</p>   |  |
| <ul style="list-style-type: none"> <li>i Make the patient comfortable, explain the procedure in detail.</li> <li>ii Check the written and informed consent (adult/minor).</li> <li>iii Wash hands thoroughly and air dry (preferred).</li> <li>iv Wear gloves, clean the periocular area with povidone iodine scrubs.</li> <li>v Proparacaine eye drops (avoid lignocaine, as this is bacteriostatic).</li> <li>vi Apply lid speculum.</li> </ul> | <ul style="list-style-type: none"> <li>viii With patient in primary gaze, introduce 30G/27G needle through the selected site on the limbus tangentially in a lamellar fashion, keeping direction oblique over the iris surface (prevent direction towards lens) with active suction.</li> <li>ix Aspirate as much aqueous and exudates/hypopyon as possible (without collapsing the AC) (approximately 0.1–0.2 ml).</li> <li>x Apply cotton tip applicator and withdraw the needle.</li> <li>xi The syringe can be sent in a sterile transport tube to the microbiology lab (Fig. 3).</li> </ul> |

- xii Administer the intravitreal antibiotics (as per the initial smear report/empirical if a delay is expected in reporting) and patch with topical povidone iodine.
- xiii The patch should be removed after half an hour and topicals started.

**Drugs and treatment protocols (Table 2)**

**Nuggets**

Primary objectives of endophthalmitis management are eradication and control of infection, management of complications and restoration of vision, in that order.

**Nuggets**

1. The aqueous should be collected with needle directed towards the exudates/hypopyon to enhance the possibility of microbial isolation and identification.

2. In an unco-operative or apprehensive patient, the fellow eye may be temporarily closed to minimize the anxiety caused by the visibility of needle/syringe.

**4. Intravitreal antibiotics**

a. Requirements

- i Basic requirements as in point 3a.
- ii Antibiotic vials (to be administered).
- iii Diluents (distilled/sterile water).
- iv Adjuvant (steroids dexamethasone).
- v 5 or 10 ml sterile syringe.

**Table 2** Outlines of management of endophthalmitis based on etiology (tailored approach warranted).<sup>7,8</sup>

Type	Most common pathogens	Initial systemic treatment	Initial intravitreal antibiotic	Need for vitrectomy	Need for IOL removal (absolute indication)
Acute post-cataract surgery	Coagulase negative Staphylococci (70%), other Gram-positive (25%), Gram-negative (fulminant)	I/V** or oral third-generation cephalosporin/ fluoro-quinolones	V+C+D*	Yes, early if severe cases/ fulminant or fungal infection	May be
Sub-acute cataract surgery	<i>Propionibacterium acnes</i>	No	V (capsular bag) and D (Intravitreal)	May be needed	Yes
Post intravitreal injection	Coagulase-negative Staphylococci, viridians Streptococci	Fluoro-quinolones or equivalent	V+C+D*	Rarely (if it is severe)	No
Filtering bleb related	Streptococci, <i>Hemophilus influenzae</i>	I/V** or oral 3 <sup>rd</sup> generation cephalosporin/ fluoro-quinolones	V+C+D*	Most cases, early in fulminant cases	No
Post traumatic	<i>Bacillus cereus</i> , Coagulase negative Staphylococci, Fungi (vegetative matter)	I/V** Vancomycin and either third-generation cephalosporins/ fluoro-quinolones	V+C+D* (Amphotericin/ Voriconazole with no steroids (if fungal))	Most cases, early in fulminant cases	Varies (always with fungal etiology)
Endogenous bacterial	<i>Staphylococcus aureus</i> , Streptococci, Gram-negative bacilli (e. g. <i>Klebsiella</i> )	I/V** or oral broad spectrum antibiotics tailored to systemic infection	V+C+D* (or amikacin)	Mostly needed	No
Endogenous fungal (mould)	<i>Aspergillus</i> , <i>Fusarium</i>	Oral voriconazole (I/V** if fulminant)	Voriconazole or amphotericin	Yes	Yes
Endogenous candida	Candida species	Oral voriconazole	Voriconazole or amphotericin	Yes if vitritis	Yes
Chronic post operative fungal	<i>Aspergillus</i> species, Candida species, <i>Curvularia lunata</i>	Oral voriconazole; rarely I/V** voriconazole or Amphotericin B (highly toxic), or oral fluconazole	Voriconazole or amphotericin B	Yes	Yes

\*V, vancomycin; C, ceftazidime/cephazoline, D, dexamethasone. (Most commonly used initial empirical drugs based on clinical presentation.)

\*\*I/V, intravenous

**Table 3** Intravitreal drugs, doses and preparation techniques of most commonly used antibiotics.<sup>9,10</sup>

S. no.	Name of antibiotic (available dose)	Intravitreal dose (per 0.1 ml)	Salient steps for preparation (1 ml tuberculin syringe)	Remarks (if any)	Frequency of repeat injections**
1	Vancomycin (500 mg)	1 mg	<ol style="list-style-type: none"> <li>1. Add 5 ml distilled water</li> <li>2. Mix well (shake)—100 mg/ml</li> <li>3. Take 0.1 ml of drug solution</li> <li>4. Dilute with 0.9 ml of sterile water</li> <li>5. Mix well (moving air bubble up and down)</li> <li>6. Discard 0.9 ml</li> <li>7. Use 0.1 ml for injection</li> </ol>	Do not mix with other drugs, as it gets precipitated (single dilution)	72 hours
2	Ceftazidime (1000 mg)	2.25 mg	<ol style="list-style-type: none"> <li>1. Add 4 ml of distilled water (250 mg/ml)</li> <li>2. Follow Steps 2–7 as in row 2</li> <li>Use dexamethasone in Step 4 if indicated</li> </ol>	Can be mixed with steroid preparation in the same syringe (single dilution)	48–72 hours
3	Amikacin (250 mg/2 ml)	125 µg (previously recommended 400 µg was highly retinal toxic)	<ol style="list-style-type: none"> <li>1. Take 0.1 ml solution (12.5 mg/0.1 ml)</li> <li>2. Follow steps 4–6 as in row 2</li> <li>3. Take 0.1 ml solution</li> <li>4. Take 0.9 ml of distilled water again and mix well</li> </ol> <p>Can be mixed with dexamethasone for final concentration (step 4)</p>	Can be mixed with steroid preparation in the same syringe (Double dilution)	24–48 hours
4	Gentamycin (80 mg/2 ml)	80 µg	<ol style="list-style-type: none"> <li>1. Take 0.2 ml of Gentamycin (8 mg/0.2 ml)</li> <li>2. Dilute with 0.8 ml of distilled water</li> <li>3. Mix well</li> <li>4. Discard 0.9 ml of solution</li> <li>5. Dilute with 0.9 ml of distilled water and mix well</li> <li>6. Discard 0.9 ml of solution</li> <li>7. Use 0.1 ml for injection</li> </ol>	Extreme retinal toxicity, rarely used now (double dilution)	72–96 hours
5	Amphotericin B (50 mg)	5 µg	<ol style="list-style-type: none"> <li>1. Add 10 ml of distilled water and mix well (5 mg/ml)</li> <li>2. Follow steps 2–6 as in row 2</li> <li>5. Again take 0.1 ml of solution and add 0.9 ml distilled water and mix well</li> <li>6. Discard 0.9 ml of solution</li> <li>7. Use 0.1 ml for injection</li> </ol>	Phototoxic, dispensed in a brown (double dilution)	?? 48 hours
6	Voriconazole (200 mg)	50–100 µg	<ol style="list-style-type: none"> <li>1. Add 19 ml of distilled water and mix well (10 mg/ml)</li> <li>2. Take 0.1 ml solution and add 0.9 ml distilled water and mix well</li> <li>2. Discard 0.5 ml of solution</li> <li>5. Take 0.5 ml of sterile water and mix well (air bubble)</li> <li>6. Discard 0.9 ml of solution</li> <li>7. Use 0.1 ml for injection</li> </ol>	(One and a half dilution)	48 hours
7	Ciprofloxacin (200 mg/100 ml)	100 µg	Directly loaded from the sterile vial and injected intravitreally, 0.05 ml	Not to be loaded from the topical preparation; since half-life is approx. 6 hours, daily injections are needed	12 hours
8	Moxifloxacin	200 µg	Take 0.05 ml of 0.5% moxifloxacin (preservative free)	Directly taken from topical preparations under sterile conditions	12 hours
9	Imipenem (250 mg)	50–100 µg	<ol style="list-style-type: none"> <li>1. Dilute with 100 ml of distilled water</li> <li>2. Take 0.2 ml (0.5 mg)</li> </ol>		Data not available

Continued

Table 3 Continued

S. no.	Name of antibiotic (available dose)	Intravitreal dose (per 0.1 ml)	Salient steps for preparation (1 ml tuberculin syringe)	Remarks (if any)	Frequency of repeat injections**
10	Piperacillin/tazobactam (2.25 g)	225 µg	Data not available	3. Dilute with 0.3 ml sterile water 4. Inject 0.05 ml	??24–48 hours
11	Carbenicillin (1 g)	2000 µg	Data not available		Data not available
12	Ticarcillin (with clavulanate (3.1 g))	3000 µg	Data not available		Data not available
13	Aztreonam	100 µg	Data not available		12 hours

\*\*All are in Phakic, nonvitrectomized eyes. Caution must be taken in interpreting the need for repeat intravitreals. Vitrectomized/aphakic eyes need more frequent injections whereas inflamed eyes have varied requirements.

#### Nuggets

Caution should be taken to avoid mixing of drugs which may get precipitated, for eg, vancomycin and ceftazidime in a same syringe.

- vi Labels for the antibiotics (for patient details), to be used later.
- b. Procedure
  - i In continuation to the steps mentioned in 3b (i–vi).
  - ii Prepare the intravitreal injections fresh maintaining adequate sterility (Table 3).
  - iii Mix the drug thoroughly with a small air bubble to dissolve the antibiotic with solvent.
  - iv Remove the air completely and dispose the excess drug to prepare the required amount.
  - v In phakic/ pseudophakic eye: with 30G needle directed toward the mid-vitreous cavity, enter through pars plana (pars plicata in children less than 1 year age) and inject the required amount of drug (loaded in 1 ml tuberculin syringe).
  - vi In aphakic eye: limbal entry with antibiotic injected into the vitreous cavity through the anterior chamber.
  - vii Apply cotton tip applicator to the injection site, examine the fundus and check eye pressure digitally.
  - viii AC paracentesis may be needed if the IOP is high and a second injection is needed.
  - ix Label the antibiotic vial and store in refrigerator (do not freeze).
  - x To be used within 3–5 days of preparation (either for topical or repeat intravitreals).
- c. In the bag technique<sup>4</sup>
  - i In cases of subacute endophthalmitis with suspected *Propionibacterium acnes* colonies sequestered in the capsular bag, a 27G needle can be directly introduced from the opposite quadrant at the limbus, gently lifting the anterior capsule and aspirating the sequestered organisms.
  - ii The intravitreal antibiotics can also be directly injected in the capsular bag behind the IOL after gently lifting the anterior capsule with the needle, taking care to inject small quantities and avoiding sudden injection (to prevent rupture of the capsular bag).

#### Nuggets

1. Initial broad spectrum empirical therapy is given based on the clinical evaluation or if a delay in the initial smear report is anticipated or if the initial report is equivocal. This should be modified immediately based on the microbiology study results.

2. The direct aspiration of capsular bag material increases yield of organisms (e.g. *Propionibacterium acnes*).

#### 5. Vitreous tap

- a To be avoided (or performed with utmost care) in phakic non-vitrectomized eyes.
- b Indicated in recurrent/non-resolving endophthalmitis in a vitrectomized eye.
- c Use a sterile 27G needle with 2 cc or 5 cc syringe, enter through pars plana, aspirate gently (0.2–0.3 ml approximately), avoiding forceful suction.

**Table 4:** Most common drugs used in endophthalmitis and their clinical profile<sup>11,12</sup>

Drug	MOA	Spectrum	DOC for	Emerging resistance
<b>Cephalosporin</b> Ceftazidime Ceftriaxone Cefazolin	Inhibit peptide crosslinking of polysaccharide chains of peptidoglycan; affects proteins in cell membrane	Gram –ve cocci, <i>P. aeruginosa</i> Serratia (not active against anaerobes), Gram +ve bacilli, Gram –ve bacilli, Enterobacter, <i>E. coli</i> Klebsiella, proteus, <i>H. influenzae</i> , Gram +ve cocci, Gram –ve bacilli, <i>E. coli</i> , Proteus, <i>H. influenzae</i>	Gram –ve Anaerobes	Acinetobacter, Enterococci
<b>Glycopeptide</b> Vancomycin	Inhibits the synthesis of precursor units of bacterial cell wall; inhibits RNA synthesis	Gram +ve cocci, MRSA, MDR <i>Staph epidermidis</i> , Clostridium, <i>Corynebacterium diphtheroids</i>	MRSA	Enterococci
<b>Aminoglycoside</b> Amikacin	Blocks protein synthesis by binding to 30S subunit of ribosomes	Second choice for Gram –ve bacilli, Pseudomonas, Enterobacter, klebsiella, <i>E. coli</i> , Serratia	Gram –ve	Gram negative Bacilli
<b>Fluoroquinolones</b> Ciprofloxacin Moxifloxacin	Topoisomerase II inhibitors	Broad spectrum against aerobic GPB, GNB, Pseudomonas, Streptococci, <i>Staph. epidermidis</i> , Actinomyces, <i>Nocardia</i> sp. Gram –ve, Gram +ve, anaerobes	Gram –ve organisms Gram +ve organisms	<i>Enterococcus faecalis</i> , <i>Streptococcus pyogenes</i> Multi-drug resistant MTB, nosocomial Gram –ve
<b>Polyenes</b> Amphotericin-B	Binds irreversible to ergosterol in cell membrane which increases membrane permeability	<i>Aspergillus</i> sp., <i>Fusarium</i> sp., Dematiaceous fungi (Curvularia, Bipolaris, Alternaria etc), Candida	<i>Cryptococcus neoformans</i>	Individual strains of Candida albicans, Candida tropicalis, Candida parapsilosis Fusarium sp. and Sporothrix schenckii
<b>Triazoles</b> Voriconazole	Inhibition of ergosterol synthesis which increases membrane permeability	<i>Fusarium</i> , <i>candida</i> , yeasts, filamentous fungi, <i>Scedosporium apiospermum</i> , <i>Acremonium</i>	Fluconazole resistant candidemia	<i>Aspergillus fumigatus</i>
Carbapenem Imipenem Ticarcillin	Inhibit cell wall synthesis Prevent cross-linking of peptidoglycan during cell wall synthesis	Gram +ve, Gram –ve, anaerobes Gram –ve bacteria	<i>Pseudomonas aeruginosa</i> , Enterococci <i>Pseudomonas aeruginosa</i> .	MRSA, pseudomonas sp., <i>Acinetobacter baumannii</i> , some <i>Acinetobacter</i> spp., <i>Bacteroides fragilis</i> , and <i>Enterococcus faecalis</i> <i>Enterobacteriaceae</i> , <i>H. influenzae</i>

MOA, mechanism of action; DOC, drug of choice; MRSA, methicillin-resistant *Staphylococcus aureus*; MDRS, multi-drug-resistant *Staphylococcus*; GPB, Gram-positive bacilli; GNB, Gram-negative bacilli

- d Keeping the same needle in situ (vitrectomized eye tends to collapse after vitreous tap), the syringe is disconnected and antibiotic loaded tuberculin syringe can be connected and injected to avoid repeat entry sites.

#### Nuggets

Vitreous tap is controversial in non-vitrectomized eyes due to possibility of vitreous traction and subsequent retinal detachment.

**Table 5:** Doses of most commonly used antibiotics in management of Endophthalmitis<sup>13,14</sup>

Antibiotic	Routes of administration				
	Topical (1% = 10 mg/ml)	Subconjunctival (mg)	Intravitreal (per 0.1 ml)	Intravenous	Infusion <sup>a</sup> (µg/ml)
Ceftazidime	50 mg/ml	100–200	2.25 mg	2–6 g daily in 2–3 divided doses	40–45
Cephazolin	50 mg/ml	100	2.25 mg	1–6 g daily in 3–4 divided doses	–
Vancomycin hydrochloride	25–50 mg/ml	25	1.0 mg	2 g daily in 2 doses	30–200
Clindamycin	50 mg/ml	15–50	1.0 mg	0.6–3.6 g daily in 3–4 divided doses	9
Imipenem/Cilastatin sodium	5 mg/ml	–	50–100 µg	2 g daily in 3–4 divided doses	16
Ciprofloxacin	3.0 mg/ml		100 µg		–
Moxifloxacin	5.0 mg/ml		150–200 µg		–
Amikacin	20–50 mg/ml (rarely used)	25	125 µg (earlier 400 µg)	15 mg/kg/day in 2–3 divided doses	8–10
Gentamycin	10–20 mg/ml (rarely used)	10–20	80 µg	3–5 mg/kg/day in 2–3 divided doses	8
Piperacillin/tazobactam	6–20 mg/ml	100	225 µg	6–12 g every 4–6 hours	–
Aztreonam	–	100	100 µg		–
Ticarcillin disodium	6–20 mg/ml	100	3000 µg	200–300 mg/kg daily in 4–6 doses	–
Carbenicillin	4–6 mg/ml	100	2000 µg	15–30 g in 4–6 divided doses	–
Penicillin G	100,000–200,000 U/ml	0.5–1 million U	–	2–18 million U daily in 4–6 doses	80
Tobramycin sulphate	10–20 mg/ml	10–20	100–200 µg	3–5 mg/kg daily in 2–3 doses	10
Natamycin	5% suspension	Not indicated	Not indicated	Extremely toxic	–
Amphotericin B	1–5 mg/ml	5–10	5 µg	–	10–20
Voriconazole <sup>b</sup>	10 mg/ml	10(Not used)	50 µg–100 µg	6 mg/kg IV every 12 hours (24 hours), then 4 mg/kg × 12 hours or 200 mg/day BD	Not used

‘–’ indicates data are not available.

<sup>a</sup> Infusion: maximum prophylactic non-toxic doses, used per-operatively.

<sup>b</sup> Shelf-life of most reconstituted antibiotics (fortified preparations) for topical use is 3–5 days except voriconazole, amikacin and tobramycin which has a shelf life of approximately 30 days

## 6. Vitreous biopsy

- a Planned along with vitrectomy (20/23/25G).
- b Initial vitreous specimen without turning on the infusion fluid (undiluted sample).
- c Approximately 0.3–0.5 ml of vitreous sample is collected.
- d Techniques
  - i 5 ml syringe connected to suction port of vitrectomy cutter, gentle manual aspiration applied by the assistant along with vitrectomy. The syringe can be sent in a sterile container to the microbiology lab (Fig. 3).
  - ii Intrector technique (Insight instruments, Inc., Stuart, FL): one port vitrectomy (23G) technique (portable, battery powered vitrectomy system), using the illumination from the operating microscope or the indirect ophthalmoscope,<sup>5</sup> used for collection of vitreous sample as an office-based technique, in selective cases.
  - iii Microbiological evaluation of the filter (rarely)/cassette used during vitrectomy.

**Nuggets**

Correct placement of infusion cannula is mandatory, so that infusion can be switched on as soon as the sample is collected, thereby avoiding the complications of hypotony. Blind cutting of vitreous is to be avoided.

**7. Special situations**

- a Pediatric/highly unco-operative patients: initial assessment can be followed by examination under anesthesia, with AC tap, intravitreal antibiotics/surgery in the same sitting.
- b Dose alterations: Vitrectomized eyes (increased frequency/daily injections intravitreally), silicone oil filled eyes (half dose injections intravitreally, due to compartmentalization), pediatric age group (half volumes injected, due to smaller globe volumes).
- c Involvement of allied sub-specialties such as cornea (for possible grafting in case of corneal/scleral involvement), glaucoma (if the filtering bleb or the drainage device needs management) and an internist (in case of endogenous endophthalmitis).
- d Consent for evisceration to be taken in fulminant cases with detailed explanation to the patient and relatives prior to performing the surgery.

**Nuggets**

Vitrectomy and/or lensectomy greatly decrease the half life of intraocularly administered drugs. Ocular inflammation, however, can either increase or decrease the rate of elimination.

**8. Microbiology procedures and inoculation methods<sup>6</sup>**

- a. Collection of intra-ocular samples
  - i Aqueous: AC tap (see Point 3).


- ii Vitreous: Vitreous tap (see Point 5)/ Vitreous biopsy (see Point 6).
- iii Others: IOL (with/ without bag contents), IOFB, suture, abscised iris tissue, collection from the vitrectomy cassette.
- iv After collection of sample, the air in the syringe is expelled and the needle is mounted into a sterile rubber cork placed in a large sterile test tube container, sealed and sent to the laboratory for smear and culture (Fig. 3).
- v In case of other material, the collected specimen is to be sent in a sterile bottle without any solution or preservative.

## b. Culture media (Fig. 4)

- i For isolation of aerobic bacteria and fungi:
  - 1 Solid media: blood agar, chocolate agar, Macconkey agar, Sabouraud's dextrose agar.
  - 2 Liquid media: brain heart infusion broth.
- ii For isolation of anaerobic bacteria:
  - 1 Solid media: Brucella blood agar.
  - 2 Liquid media: thioglycollate broth.

## c. Inoculation and sending the samples to microbiology lab

- i One drop each to be carefully inoculated (not to be spread) in agar media in the center of the plate and into the Brain heart infusion broth and thioglycollate broth.
- ii It is essential that the inoculation of media is done first (since the number of micro-organisms are likely to be low, every chance needs to be given to them to multiply and grow in the culture media)
- iii Growth for anaerobic micro-organisms and fungus is observed for 12 days.
- iv Samples in odd hours may be inoculated in Brain heart infusion broth and thioglycollate



**Figure 4.** Commonly used solid and liquid culture media for inoculation of the samples.



broth and kept at room temperature, 25–30°C (with label). The remaining sample can also be capped onto the needle and kept in the refrigerator at 4°C compartment to be transported at the earliest (for PCR and making smears).

#### Nuggets

1. The initial smear report should be obtained at the earliest (within 45 minutes)
2. The initial smear reports consist of Gram's stain, and KOH/Calcoflour preparation
3. Growth of organisms in more than one plate is considered positive. Subsequently antibiogram tests are conducted
4. Polymerase chain reaction (PCR) can detect the genomes of live as well as dead organisms, so careful interpretation of the results should be made and to be correlated clinically.

#### Endogenous endophthalmitis

The common organisms implicated are

- 1 Endocarditis: *Staphylococcus aureus*, Streptococci (alpha, beta or gamma)
- 2 Liver abscess: *Klebsiella pneumoniae*
- 3 Long-term hospitalization: *Candida* species (most common *Candida albicans*), and filamentous fungi (*Aspergillus*) rarely

Systemic antibiotics (antibacterials/antifungals) play a key role in the management of endogenous endophthalmitis. Since the half-life of intravitreal antibiotics is short, the systemically administered antibiotics are given to maintain therapeutic levels for prolonged periods. The investigations including the samples for microbiology tests should ideally be sent before starting systemic antibiotics.

#### Role of systemic steroids

Important in combating the intraocular inflammation that is particularly severe due to the release of toxins from the infecting organisms. Caution in patients with diabetes and active Koch's infection

is advised, and contra-indicated in fungal endophthalmitis.

#### Acknowledgements

The authors thank Dr. Muna Bhende, Dr. Vikram Koundanya, Dr. Vishvesh Agarwal from Shri Bhagwan Mahavir Vitreoretinal Services. They also thank entire team from Shri Bhagwan Mahavir Vitreoretinal Services, Jadhavbai Nathmal Singhvee Glaucoma Services and L&T Microbiology Research Centre.

#### References

1. American Academy of Ophthalmology. Basic and Clinical Science Course: Section 12: Retina and Vitreous, 2004–5. San Francisco: American Academy of Ophthalmology, 2005:328–31.
2. Safneck JR. Endophthalmitis: a review of recent trends. *Saudi J Ophthalmol.* 2012;26(2): 181–9.
3. Ang GS, Varga Z, Shaarawy T. Postoperative infection in penetrating versus non-penetrating glaucoma surgery. *Br J Ophthalmol.* 2010;94(12):1571–6.
4. Gopal L, Nagpal A, Verma A. Direct aspiration of capsular bag material in a case of sequestered Endophthalmitis. *Indian J Ophthalmol.* 2008;56(2):155–57.
5. Oshima Y, Kadosono K, Yamaji H, Inoue M, Yoshida M, Kimura H, Ohji M, Shiraga F, Hamasaki T; Japan Microincision Vitrectomy Surgery Study Group. Multicenter survey with a systematic overview of acute onset Endophthalmitis after transconjunctival microincision vitrectomy surgery. *Am J Ophthalmol.* 2010;150:716–25.
6. <http://www.ijmm.org/documents/ocular.pdf>.
7. Durand ML. Endophthalmitis. *Clin Microbiol Infect.* 2013;19:227–34.
8. American Academy of Ophthalmology, section 12. Retina and vitreous. pp 355–8. 2011–12.
9. Barry P, Cordovés L, Gardner S. ESCRS guidelines for prevention and treatment of endophthalmitis following cataract surgery: data, dilemmas and conclusions. Paper presented at: the European Society of Cataract and Refractive Surgeons; 2013; Dublin, Ireland
10. Radhika M, Mithal K, Bawdekar A, Dave V, Jindal A, Relhan N, Albini T, Pathengay A, Flynn HW. Pharmacokinetics of intravitreal antibiotics in endophthalmitis. *J Ophthalmic Inflamm Infect.* 2014;10:22
11. Bartlett JD, Jananus SD. Clinical Ocular Pharmacology, 4th edition. Butterworth-Heinemann, Boston.
12. Ellis D. Amphotericin B: spectrum and resistance. *J Antimicrob Chemother.* 2002;49(Suppl. 1):7–10.
13. Peyman GA, Duan M. Prophylaxis of endophthalmitis. *Ophthalmic Surg.* 1994;25:67.
14. Lemley CA, Han DP. Endophthalmitis: a review of current evaluation and management. *Retina.* 2007;27(6):662–80.

**How to cite this article** Verma A, Muralidharan V, Nigam E. Endophthalmitis: Current Trends, Drugs and Protocols, *Sci J Med & Vis Res Foun* 2015;XXXIII:61–70.

# Macular Buckle in Myopia

Pradeep Susvar and S. Vinay Kumar

Shri Bhagwan Mahavir  
Vitreoretinal Services,  
Sankara Nethralaya

## Correspondence to:

Pradeep Susvar,  
Senior Consultant,  
Shri Bhagwan Mahavir  
Vitreoretinal Services,  
Sankara Nethralaya.  
E-mail: drpds@snmail.org

## Introduction

Pathologic myopia is one of the leading cause of secondary visual impairment worldwide and the most frequent cause in Asian subcontinent. Visual impairment in these eyes with pathologic myopia is mainly due to the development of different types of myopic maculopathies, closely associated with the type and grade of the staphyloma.<sup>1</sup> Various authors have classified them into tessellated fundus, lacquer cracks and patchy atrophy, diffuse chorioretinal atrophy, lacquer cracks, patchy chorioretinal atrophy, CNV, macular atrophy and posterior staphyloma.<sup>2</sup> Macular hole with or without macular retinal detachments, myopic foveal schisis are established associations of the posterior staphyloma.<sup>1</sup> These complications are managed surgically by pars plana vitrectomy (PPV) with internal limiting membrane (ILM) peeling with intraocular tamponade. Scleral shortening procedures, episcleral buckling are some of the additional procedures performed to take care of the posterior staphyloma component pathological myopia with variable surgical success.<sup>3</sup>

## Pathophysiology

The pathogenesis of RD secondary to macular hole and retinoschisis in high myopia with posterior staphyloma are<sup>4,5</sup>

- 1 Posterior staphyloma leading to disparity in the length of the sclera and retina (mismatch).
- 2 Anteroposterior traction caused by the vitreous.
- 3 Tangential traction due to abnormal rigid ILM, stretched retinal vessels or epiretinal membrane.

Other possible explanations were weak adhesion between the neurosensory retina and retinal pigment epithelium due to the severe myopic chorioretinal atrophy and an incomplete detachment of the posterior hyaloid that will increase the anteroposterior and tangential traction on the retina.

The macular buckle is proposed to support the posterior globe to counteract all the mechanisms involved in such cases. Buckle changes the configuration of the posterior pole from the concave profile of posterior staphyloma to a plano/convex protruding contour thereby relieving anteroposterior traction, tangential traction and sclero retinal mismatch (Fig. 1).

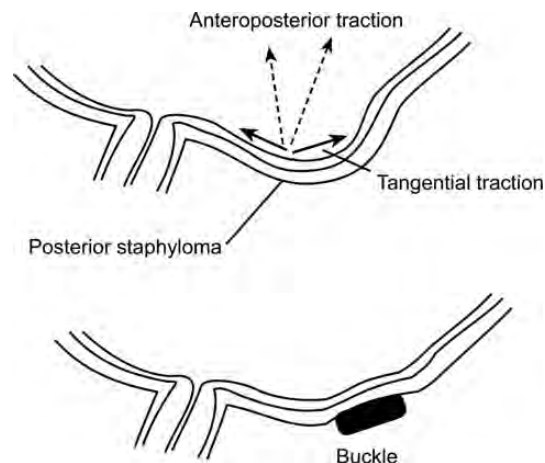


Fig. 1.

## History of macular buckle

1957: Macular buckling was described for the first time by Charles L. Schepens, the father of modern retinal surgery, using a radially placed polyethylene tube.<sup>6</sup>

1966: Rosengren B described a silver ring and plomb technique to indent the macula. The ring is attached to the limbus and an arm fixed to the ring has a terminal ball, which was made to indent the macula. Photocoagulation is done after a day or two once the fluid is absorbed. The ring and plomb are removed after 4 weeks.<sup>7,8</sup>

1974: Theodossiadis used a silastic sponge rod placed between the inferior oblique insertion and the optic nerve. The rod was stretched vertically across the macula by fixing sutures to produce the required indentation. He followed his patients for upto 15 years.<sup>9</sup>

1980: Ando introduced the Ando plombe which is described in detail later.<sup>10, 11</sup>

## Evolution of surgical treatment for myopic macular schisis, macular hole and RD

PPV with ILM peeling has been effective in terms of anatomical and functional success in the treatment of macular schisis and macular holes associated with high myopia.<sup>12-14</sup> Complications include formation or persistence of macular hole, macular hole retinal detachment (MHRD) and visual loss.<sup>15-16</sup> Success of closure in these myopic macular holes following surgery is less than the idiopathic holes in emmetropia.<sup>17</sup> Ikuno et al showed 25% of macular hole closure following surgery in myopia with macular hole and foveoschisis with posterior staphyloma.<sup>18</sup> Failure

of vitrectomy with ILM peeling in such cases lead to think about the other causative factors responsible for the macular complications in myopic eyes with posterior staphyloma. Cases which had failures following vitrectomy led one to consider additional or supplemental procedures which could negate the mismatch between the staphyloma and retinal contour. This led to the surgical options of macular buckle in myopic eyes with posterior staphyloma

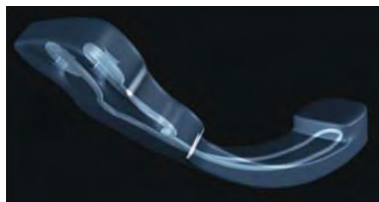#### Indications

- Myopic macular retinoschisis with posterior pole staphyloma with recent decrease in visual acuity.
- Posterior pole detachment associated with myopic macular hole with posterior staphyloma.
- Failed and recurrent cases of macular hole with or without RD following vitrectomy with or without tamponade.
- Optic disc pit maculopathy.

#### Macular buckle types

- Ando plombe
- T-shaped macular buckle
- AJL macular buckle
- L-shaped macular buckle
- Adjustable macular buckle
- Wire-strengthened sponge explant

#### Ando's plombe (Ondeko Corp)



Ando plombe consists of a T-shaped semirigid silicone rubber rod internally reinforced with titanium wires and an indenting head at one end. The length of the plombe is either 25 or 27 mm from head to tail, selected according to the size of globe. The size of the head is 4–5 mm. Mateo et al. coupled Ando's plombe with an internal 30-G optical fiber to enhance the visualization to place the indenting head correctly under the fovea.<sup>19</sup> Advantages include easy to insert the buckle, shape memory, customization of buckle with its embedded wire and eliminates the need for sutures on the staphylomatous sclera near macular area. Disadvantages include its stiffness, limitations in

adjustment of buckle height, a less accurate positioning. The long-term safety of metal wire which is embedded in the Ando's plombe is not known.

#### T-shaped macular buckle {France Chirurgie Instrumentation (FCI), Paris, France}



The T-shaped macular buckle<sup>20</sup> is created by threading a 4-mm-wide solid silicone band through a 7-mm solid silicone macular wedge (Morin-Devin 'T'-shaped macular wedge) with a biconvex end. Macular wedge is negotiated under the lateral rectus muscle, manoeuvred further to be placed posteriorly under the staphyloma area. The 4-mm solid silicone bands are mobilized under the vertical muscles, behind the obliques to secure on to the nasal aspect, either side of the medial rectus. Advantages of T-shaped macular buckle are that it allows the adjustment for lengthening or shortening the band anteriorly while sliding the macular plate in the coronal plane; it does not require posterior sutures or direct access to the posterior pole, no need for muscle disinsertion which carries the risk of post-operative pain and diplopia. Disadvantage includes possibility of improper alignment under the fovea.

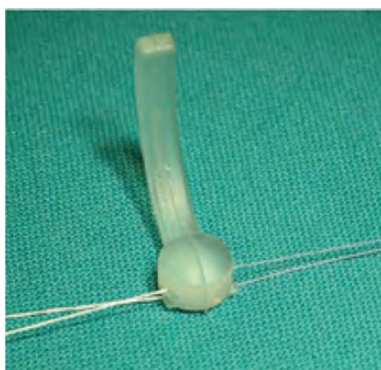
#### AJL macular buckle



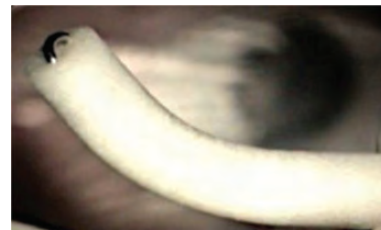AJL macular buckle is made up of PMMA material covered by silicone in order to increase its biocompatibility. It has an indentation area with a spherical helmet in its superior area to indent the macular area. The arm's length and curvature is customized depending on the patient's specific eye. It can be supplied with an optic fiber light probe for the accurate positioning of the head under the fovea.

*L-shaped macular buckle*

L-shaped buckle is prepared using a silicone sponge (Labtician 507 oval sponge), 7 mm large and 5 mm thick and 3 cm long. A malleable titanium stent (Mod MCP6TP, Tekka, Pesaro, Italy) 15 mm long, 2 mm wide and 0.5 mm was inserted and hidden into the tunnel. The sponge could then be bent to obtain an L-shaped buckle by creating a 90° angle to fashion the curvature accordingly. Advantages are that it can be easily prepared in the operation theatre and the technique can be performed without the need of specially designed buckles, which are not available easily in all countries. Disadvantages include the unknown long-term safety of the titanium inside the orbit.<sup>21</sup>

*Adjustable macular buckle (AMB)*

The AMB is made up of silicone rubber, consisting of a handle or stalk designed for radial positioning and a terminal plate intended to indent the macular area. Two lateral winglets at the terminal plate helps to pass suture through it. The two mersilene sutures are brought on either side of the medial rectus, fixed to the sclera anterior to the equator. This procedure requires lateral rectus disinsertion. Postoperatively the buckle effect can be adjusted using these sutures under local anaesthesia.<sup>22</sup>

*Wire-strengthened sponge explant*

It consists of a 7 mm silicone sponge strengthened with a 0.5 mm orthodontic steel wire that is originally used for dental braces. First, the wire is bent into U shape at the middle with 2 mm separation between the 2 arms. Then, the wire is inserted inside the sponge and fed through its whole length. The distal end is bent according to the eyes which help to indent the macula.<sup>23</sup>

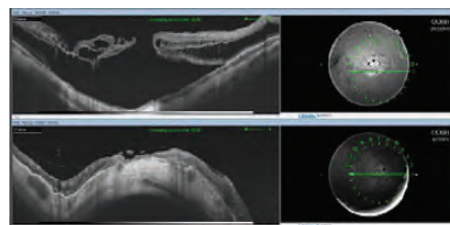
**Limitations of macular buckle**

- Possible damage to nerves and vessels in the posterior pole.
- Precised alignment of the buckle under the fovea is of concern.
- Thin sclera increases the risk of perforation and erosion is more.

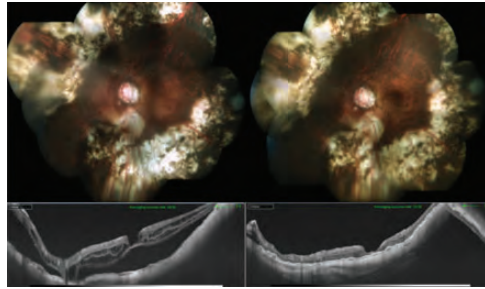
Precise alignment of the buckle under the fovea can be achieved by either

- External posterior landmarks.
- Trans illumination.
- Endo illumination.
- Using illuminated optical fiber along with the macular buckle.

We had an initial experience of three cases operated using the T-shaped macular wedge implants. Indications were recent central visual impairment due to progressive schisis, macular hole with macular detachment and persistent chorioretinal mismatch at the staphyloma in an oil filled eye. One patient operated for the staphyloma associated macular hole with localized detachment, had the macular buckle along with vitrectomy, ILM peeling and tamponade. We noted the anatomical closure of the macular hole and the foveal attachment as early as fourth post-operative period.



Another case had a persistent lamellar hole with a retinochoroidal mismatch post vitrectomy. This case was operated for the macular buckle alone in the oil filled eye. Patient had a progressive visual improvement with a gradual absorption of the subretinal fluid and the retinal apposition over a period of 5 months. Our initial short experience has been quite promising in terms of achieving anatomical restoration of the retina to match the contour of the ocular coats.



### Complications

The intraoperative complications include inadvertent globe perforation, injury to vortex veins, ciliary vessels and nerves, malposition of the buckle, optic nerve abutting, subretinal hemorrhage, choroidal detachment and threatening suprachoroidal hemorrhage intraoperatively. Late complications include buckle displacement, exposure, infection, choroidal neovascular membrane progression, restriction of eye movements, diplopia, focal retinal pigment epithelium atrophy due to circulatory disturbances.<sup>24</sup>

### Conclusion

Macular buckle can be a good option for myopic posterior staphyloma-related macular conditions such as progressive macular schisis, macular hole and posterior pole RD. The technique requires appropriate case selection and has a good anatomical and functional success as reported in many of the studies. Detection and correction of the retinoscleral mismatch would help improve functional outcomes in these eyes with high myopia-related maculopathy.

### References

- Hsiang HW, Ohno-Matsui K, Shimada N, et al Clinical characteristics of posterior staphyloma in eyes with pathologic myopia. *Am J Ophthalmol.* 2008;146(1):102-10.
- Hayashi K, Ohno-Matsui K, Shimada N, et al Long-term pattern of progression of myopic maculopathy: a natural history study. *Ophthalmology.* 2010;117(8):1595-611.
- Bagolini B, Ravalico G. Surgical treatment of retinal detachment with macular hole [Article in French]. *Arch Ophthalmol Rev Gen Ophthalmol.* 1973;33:553-8.
- Ponozzo G, Mercanti A. Optical coherence tomography findings in myopic traction maculopathy. *Arch Ophthalmol.* 2004;122:1455-60.
- Ikuno Y, Gomi F, Tano Y. Potent retinal arteriolar traction as a possible cause of myopic foveoschisis. *Am J Ophthalmol.* 2005;139:462-7.
- Schepens CL, Okamura ID, Brockhurst RJ. The scleral buckling procedures. I. *Surgical techniques and management. AMA Arch Ophthalmol.* 1957;58(6):797-811.
- Rosengren B. The silver plomb method in macular holes. *Trans Ophthalmol Soc UK.* 1966;86:49-53.
- Rosengren B. The silver plomb method in amotio retinae: clinical experience and results. *Bibl Ophthalmol.* 1966;70:253-6.
- Theodosiadis G. Treatment of retinal detachment arising from macular hole. *Mod Probl Ophthalmol.* 1974;12:322-9.
- Ando F. Use of special macular explant in surgery for retinal detachment with macular hole. *Jpn J Ophthalmol.* 1980;24:29-34.
- Ando F. Improvement of surgical procedure for retinal detachment with macular hole and post-operative visual acuity. *Jpn J Clin Ophthalmol.* 1980;35:1179-83.
- Kobayashi H, Kishi S. Vitreous surgery for highly myopic eyes with foveal detachment and retinoschisis. *Ophthalmology.* 2003;110:1702-7.
- Kanda S, Uemura A, Sakamoto Y. Vitrectomy with internal limiting membrane peeling for macular retinoschisis and retinal detachment without macular hole in highly myopic eyes. *Am J Ophthalmol.* 2003;136:177-80.
- Ikuno Y, Sayanagi K, Ohji M, et al Vitrectomy and internal limiting membrane peeling for myopic foveoschisis. *Am J Ophthalmol.* 2004;137:719-24.
- Benhamou N, Massin P, Haouchine B, et al Macular retinoschisis in highly myopic eyes. *Am J Ophthalmol.* 2002;133:794-800.
- Hirakata A, Hida T. Vitrectomy for myopic posterior retinoschisis or foveal detachment. *Jpn J Ophthalmol.* 2006;50:53-61.
- Mitry D, Zambarakji H. Recent trends in the management of maculopathy secondary to pathological myopia. *Graefes Arch Clin Exp Ophthalmol.* 2012;250(1):3-13.
- Ikuno Y, Sayanagi K, Oshima T, et al Optical coherence tomographic findings in macular holes and retinal detachment after vitrectomy in highly myopic eyes. *Am J Ophthalmol.* 2003;136:477-81.
- Mateo C, Medeiros MD. Microluminated ando plumbe for optimal positioning in highly myopic eyes with vitreoretinal diseases secondary to posterior staphyloma. *JAMA Ophthalmol.* 2013;131, Number 10
- Devin F, Tsui I, Morin B, et al T-shaped scleral buckle for macular detachments in high myopes. *Retina.* 2011;31(1):177-80.
- Parolini B, Frisina R, Pinackatt S, et al A new L-shaped design of macular buckle to support a posterior staphyloma in high myopia. *Retina.* 2013;33(7):1466-70.
- Stirpe M, Ripandelli G, Rossi T, et al A new adjustable macular buckle designed for highly myopic eyes. *Retina.* 2012;32(7):1424-7.
- Mortada HA. A novel episcleral macular buckling: wire-strengthened sponge explant for recurrent macular hole and retinal detachment in high myopic eyes. *Med Hypothesis Discov Innov Ophthalmol.* 2013;2(1):14-9.
- Siam AL, El Maamoun TA, Ali MH. Macular buckling for myopic macular hole retinal detachment: a new approach. *Retina.* 2012;32:748-53.

**How to cite this article** Pradeep S, Vinay Kumar S. Macular Buckle in Myopia, *Sci J Med & Vis Res Foun* 2015; XXXIII:71-74.

# Optical Coherence Tomography: Newer Techniques, Newer Machines

KP Mohana, Debmalya Das and Muna Bhende

Shri Bhagwan Mahavir  
Vitreoretinal Services,  
Sankara Nethralaya

**Correspondence to:**  
Debmalya Das,  
Associate Consultant,  
Shri Bhagwan Mahavir  
Vitreoretinal Services,  
Sankara Nethralaya.  
E-mail: drmuna@snmail.org

## Introduction

Since 1991, when optical coherence tomography (OCT) was first introduced as a tool for investigation in ophthalmology,<sup>1</sup> OCT has become the mainstay in retinal imaging and, in some situations, has supplanted fundus fluorescein angiography which is regarded, even today, as the gold standard for investigations in choroidal and retinal disorders. By definition, OCT represents a non-invasive method for cross-sectional imaging of the internal retinal structures through the detection of optical reflections and echo time delays of light, using low coherence interferometry to subsequently produce in vivo two-dimensional images of internal tissue microstructure.<sup>1,2</sup>

Initially, the time domain (TD) technology was used (Stratus OCT, Carl Zeiss Meditec), which employed a mobile reference arm mirror that sequentially measured light echoes from time delays with an acquisition speed of 400 A scans/second and axial resolution of 810  $\mu\text{m}$ .<sup>2,3</sup> TD OCT was limited by longer acquisition times (due to a mobile reference mirror), limited image sampling (which potentially overlooked smaller lesions), motion artifacts and lack of patient cooperation.<sup>4,5</sup>

Fourier domain or spectral domain (FD/SD) OCT succeeded the TD OCT. With a central wavelength of 800–850 nm, a stationary reference arm, a high-speed spectrometer, and a charge-coupled device (CCD) line scan camera these OCTs had an increased acquisition speed of 25,000–52,000 A scans/second, with axial resolution of 37  $\mu\text{m}$ , significantly improved signal-to-noise ratio, reduction in motion artifacts, increased area of retinal coverage and better visualization of individual retinal layers.<sup>3</sup> They were also able to create three-dimensional (3D) topographic maps with precise registration.<sup>2</sup> Imaging resolution and penetration was further enhanced by averaging and enhanced depth imaging (EDI). However, axial resolution and acquisition speed in SD OCT were limited by the limitations of CCD line scan cameras<sup>4,5</sup> and SD OCT was still subject to motion artifacts, segmentation artifacts and interinstrument comparability.<sup>3,5</sup>

Limited resolution due to infrared radiation absorption by ocular structures, limited axial and lateral resolution due to image scattering from ocular structures and restricted numerical aperture of the optical system respectively, in both TD and SD OCT, were the major disadvantages that prompted researchers to look for newer technologies.<sup>6</sup>

## SD-OCT scanning laser ophthalmoscopy systems

Currently, the machines that are using the confocal scanning laser ophthalmoscopy (cSLO) system are the Optical Coherence Tomography RS-3000 Advance from NIDEK, Cirrus HD-OCT 5000 with FastTrac, OCT/SLO Combination Imaging System from Optos, OPKO Spectral OCT/SLO Combo Imaging System and the Spectralis OCT. We will be discussing the Spectralis OCT in details along with the added technologies for better imaging.

## Spectralis OCT

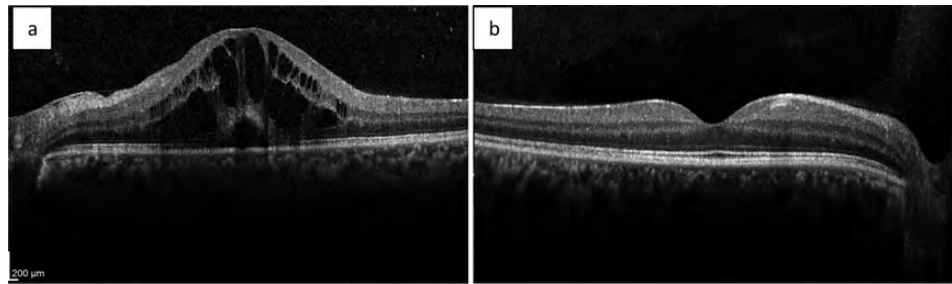
Spectralis OCT (Heidelberg Engineering, Heidelberg, Germany) is a dual-beam SD OCT and cSLO system that acquires transectional images or volume scans of the retina and an infrared reference image simultaneously. A real-time eye tracker couples cSLO and SD OCT scanners to position and stabilize the OCT scan on the retina which leads to highly reproducible retinal thickness measurements. High-speed imaging (40,000 A scans/second) allows an increased number of acquired B scans resulting in greater retinal coverage and high-definition 3D images and more detailed retinal thickness maps with less need of data interpolation in a short examination time. The excellent reproducibility of retinal thickness measurements with this technology can be attributed to improved image resolution, imaging speed, scan coverage, retinal segmentation algorithms and to the eye tracking mechanism. To improve the images, image averaging (Fig. 1) has been used to achieve high-contrast and low-speckle noise. Simultaneous real-time FFA and OCT and ICG and OCT is possible with this machine.

## Enhanced Depth Imaging

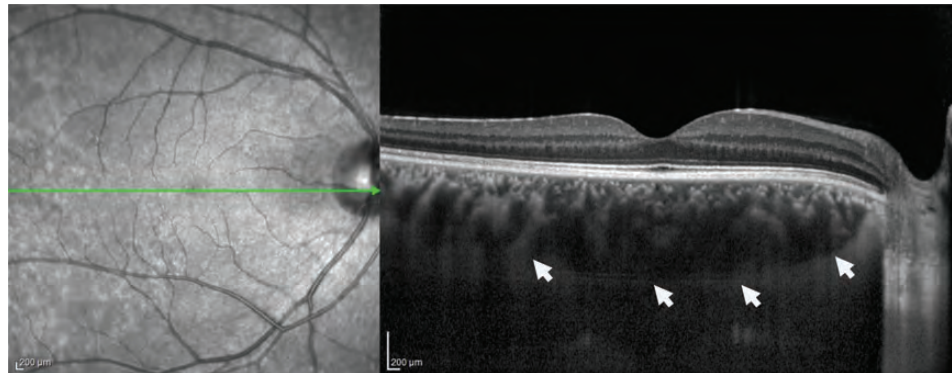
Spaide<sup>7</sup> was the first to describe visualization of the choroid after moving the zero delay line deeper into the eye, focusing the OCT scanner on the choroid instead of the retina. This is known as EDI OCT (Fig. 2). This technique has enabled the visualization of structures lying deeper in the eye.

## En face OCT

'En face' OCT (eOCT) imaging is an imaging technique derived from SD OCT. It produces frontal sections of retinal layers, also called 'C-scan OCT'. Optical Coherence Tomography Retina Scan Duo from NIDEK, Zeiss Swept Source OCT (prototype, not yet FDA cleared) and deep range imaging



**Fig. 1.** (a) OCT image taken in Spectralis OCT showing CME and SRF. (b) Normal OCT scan with image averaging of 100 scans.



**Fig. 2.** EDI of a normal eye. Arrows indicate the Chorio-scleral interface.

(DRI)-OCT; Topcon Japan, are able to take ‘en face’ OCT. Optovue and Zeiss OCT also has frontal scans adopted to retinal concavity and can take 3D and ‘En face’ OCT showing irregularities at ILM and RPE layer. This novel technology offers a deeper insight into the understanding and follow-up of macular diseases especially age-related macular degeneration. Unlike conventional OCT, eOCT processes a series of transverse scans through tissue at equally distributed and specific depths, determined by modern optical sources capable of achieving depth resolutions upto 3 mm.<sup>8,9</sup>

#### **Intraoperative OCT**

##### *Microscope mounted OCT*

The use of intraoperative SD OCT help surgeons to better delineate tissue structures, reducing surgical times and limiting the need for potentially toxic stains and excessive illumination.<sup>12</sup> Microscope mounted (MM) OCT can scan a 12-mm field of view by implementing a superluminescent diode with a center wavelength of 840 nm, allowing real-time cross-sectional analysis of tissue structures. MM OCT was designed to work with the optical path of the Oculus BIOM 3 suspended from a Leica M841 ophthalmic surgical microscope, and it provides a high magnification telescope with a large field of view to the view port of the surgical microscope. MM OCT is stabilized and utilizes a common focal plane to the microscope

optical path and hence gives a better image when compared with the handheld OCT. However, it is still limited by its 840-nm center wavelength and lateral resolution.<sup>10</sup>

The Rescan 700, Carl Zeiss, is a real-time intraoperative SD-OCT that can be fully integrated into the OPMI Lumera 700 microscope. Key functions of the OCT system can be controlled from the microscope’s foot pedal, so the surgeon can take videos, snapshots and 3-D OCT images without looking up or stopping the surgery. The Rescan allows the surgeon to see the surgical field in both a planar view and a cross-sectional view simultaneously, in real time. Haag-Streit’s intraoperative iOCT system, developed by OptoMedical Technologies in Lübeck, Germany, attaches to the camera port of the microscope; data are displayed on a screen mounted on the microscope. The screen is also used to operate the system. The device follows the zoom and focus of the microscope so the scanned area matches the area being viewed, and scans and images can be saved for future review. Surgeons report that the device can reveal structures to a depth of ~4.2 mm in air and 3.1 mm in water, with a resolution of ~10 µm.

#### **Handheld OCT**

Ivue from Optovue and Bioptigen’s Envisu C2300 Spectral Domain Ophthalmic Imaging System are designed for handheld or microscope-mounted use

for real-time imaging during ophthalmic surgical procedures, compatible with most operating microscopes. Stability of the instrument and hence the picture quality and maintenance of a sterile surgical field remains an issue with handheld OCT.

#### Swept source OCT

Swept source (SS) OCT utilizes a narrowband light source with central wavelength of 1050 nm and with a short cavity swept laser (instead of a super luminescent diode laser as in previous OCTs) that can emit different frequencies of light which are then rapidly tuned over a broad bandwidth.<sup>2,5,11</sup> It uses a high-speed complementary metal oxide semiconductor (CMOS) camera (instead of a spectrometer and CCD camera in conventional SD OCT) and two parallel photodetectors to achieve 100,000–400,000 A scan/second with 5.3- $\mu\text{m}$  tissue axial resolution over a 4-mm imaging range. The small area, high-density imaging, extensive B scan averaging, reduced fringe washout depth, longer imaging range, higher detection efficiencies, and the ability to perform dual balanced detection allows imaging down to the level of individual photoreceptors, particularly when coupled with adaptive optics.<sup>5</sup> These advantages also allow less artifacts and better penetration through ocular media opacities. The long imaging range ( $\sim 7.5$  mm) also allows a better view of the vitreo-retinal interface as well as the choroid in a single frame with an enhanced sub-retinal pigment epithelium (RPE) imaging without employment of EDI (Fig. 3) or full-depth imaging.<sup>4</sup> However, it is still subject to some blur artifacts and image distortion.<sup>12</sup> Improvements in dynamic retinal tracking and registration algorithms have helped to eliminate some of these artifacts to allow improved resolution. The DRI OCT-1 Atlantis and Zeiss SS-OCT prototype (investigational device, not FDA cleared) are based on this system.

#### Widefield OCT

Widefield OCT employs swept source technology to evaluate larger portions of the central retina (Fig. 4). Optovue (Fremont, CA) Avanti RTVue-XR widefield system uses the SD technology and can

obtain 70,000 A scans/second. The Avanti RTVue-XR can create 12 mm  $\times$  9 mm B scans, and its active eye tracking enhances image stability. The Optovue system offers 3- $\mu\text{m}$  digital resolution, providing detailed imaging of both the choroid and the retina.

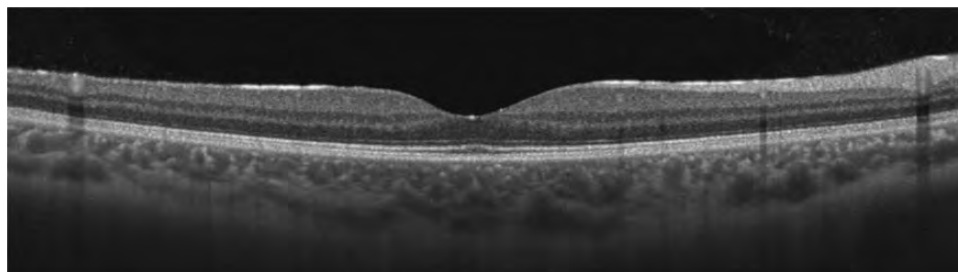
Ultra-high-speed SS OCT, using a 1050–1060 nm FD mode locked laser, collects 1900  $\times$  1900 A scans with a roughly 70° angle of view ( $\sim 1$  cm<sup>2</sup>) in 36 seconds with image acquisition speeds between 684,000 and 1,368,700 A scans/second. These are then consolidated into a 4 megapixel high-definition image. Good choroid and choroidal/scleral interface penetration can also be achieved with axial resolution of 6.7–19  $\mu\text{m}$ .<sup>13,14</sup>

#### Adaptive optics OCT

Adaptive optics corrects for higher-order ocular aberrations during image acquisition, allowing improved lateral resolution and a near-cellular-level resolution.<sup>15,16</sup> Ultra-high-resolution adaptive optics OCT (AO OCT) uses a high-speed CMOS camera with a novel image registration/dewarping algorithm to limit motion artifacts, increase lateral resolution, reduce speckle and enhance sensitivity.<sup>14</sup> Ultra-high-resolution, AO, spectral-domain OCT (UHR-AO-OCT) has an isotropic 3D resolution of 3  $\times$  3  $\times$  3  $\mu\text{m}^3$  in the retinal tissue. With a pupil diameter of more than 6 mm, lateral resolution of 23  $\mu\text{m}$  can be achieved, which is sufficient for the resolution of individual cones and of cross sectional profiles of individual retinal layers.<sup>14</sup> In combination with an adaptive optics slit lamp ophthalmoscope, AO OCT can acquire both OCT and SLO in vivo with a resolution of 3.5  $\mu\text{m}$ .<sup>16</sup>

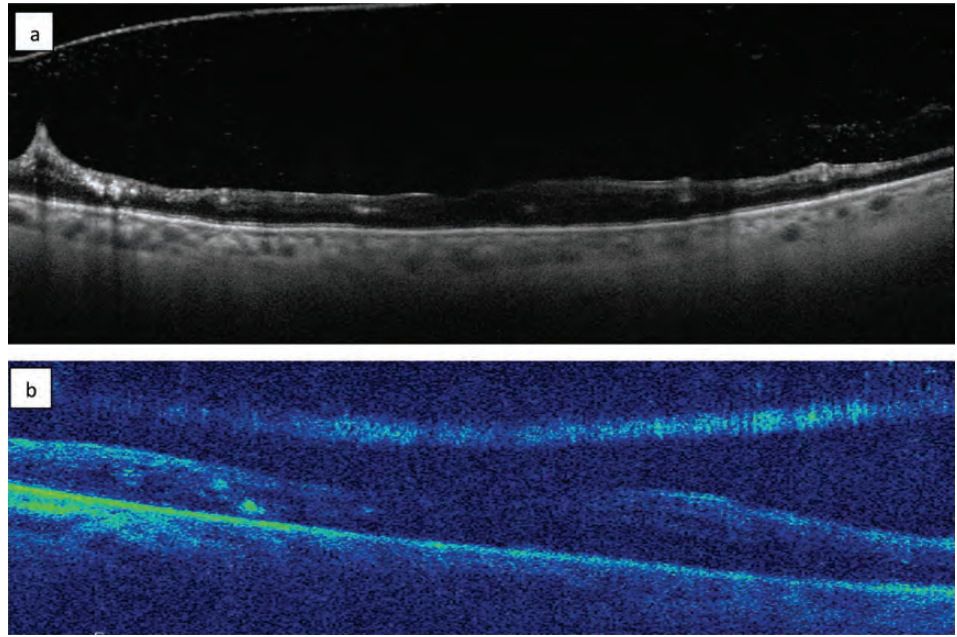
#### Optical microangiography

Optical microangiography (OMAG) technology utilizes an 840-nm wavelength with an A scan rate of 27,000 Hz and an axial resolution of 8  $\mu\text{m}$  to image a 7.4  $\times$  7.4 mm<sup>2</sup> area of the posterior segment, allowing volumetric map acquisition.<sup>17</sup> OMAG in combination with widefield OCT can perform vascular perfusion mapping, down to the capillary level comparable to fluorescein and indocyanine green angiography. The technology, though commercially available in Optovue



**Fig. 3.** Swept source OCT scan of a normal retina showing chorio-scleral interface clearly without EDI.





**Fig. 4.** 12-mm OCT scan of proliferative diabetic retinopathy with vitreous hemorrhage done on (a) Swept source OCT revealing peripheral retinal traction which is missed on (b) a regular Spectral Domain OCT. Note the relative improvement in the visualization of the retinal surface on the Swept source OCT image even in the presence of media haze due to vitreous hemorrhage.

(Fremont, CA) RTVue-XR Avanti high speed, widefield and angiovue OCT system, currently has several limitations in terms of image quality in certain situations such as macular edema and atrophy and needs further refinement.

#### Doppler OCT

Doppler OCT (D-OCT) is still under development, a prototype. D-OCT, by measuring the Doppler shift and relative angle between the OCT beam and a blood vessel, assess the blood flow velocity.<sup>2,18</sup> D-OCT (840 nm wavelength, axial resolution of 5  $\mu\text{m}$ , transverse resolution of 20  $\mu\text{m}$ ) can measure retinal blood flow, and can detect any alteration of the same even in the absence of any structural loss and hence opens up a new frontier in monitoring and management of retinal and optic nerve vascular diseases and the patients at risk.<sup>18</sup> Blood flow measurement can be accessed from the transection of all branch retinal arteries and veins by eight circular scans, acquired in  $\sim 2$  seconds, each composed of 3000 axial scans and then summing all blood flow measured in the veins. The background axial inner retinal tissue boundary motion is compared with that of the vessel wall to attain the net Doppler shift, produced by blood flow.<sup>19</sup>

#### Polarization sensitive OCT

Like D-OCT, polarization-sensitive (PS) OCT is a prototype which can be used for functional tissue assessment by means of evaluation of light polarization which allows individual retinal layer identification by measurement of cross-sectional and

volumetric birefringence, contrasting between birefringent layers and other retinal layers.<sup>2,20,21</sup> PS OCT simultaneously measures intensity (conventional OCT images), retardation and optic axis orientation to distinguish polarization preserving tissue, birefringent tissue (Retinal nerve fiber layer, Henle's layer, sclera, fibrotic tissues) and polarization scrambling tissue (RPE).<sup>21</sup> Light transmitted through the RPE maintains the same polarization state and degree of retardation as images below and above the RPE layer, allowing assessment of RPE damage.<sup>21</sup>

#### Conclusion

With enhanced ability to image the choroid, retina and vitreous, our diagnostic capabilities are greater than ever. These advancements have revolutionized ophthalmic practice over the last decade. Further innovations in both hardware and software technologies are expected to aid in the assessment of chorioretinal diseases in more detail in future. OCT is here to stay.

#### References

1. Huang D, Swanson EA, Lin CP, *et al.* Optical coherence tomography. *Science*. 1991;254:1178–81.
2. Duker JS. OCT technology: what is coming? Paper presented at Annual Meeting of the European Society of Retina Specialists, Rome, Italy, January 28, 2012.
3. Sull AC, Vuong LN, Price LL, *et al.* Comparison of spectral/Fourier domain optical coherence tomography instruments for assessment of normal macular thickness. *Retina*. 2010;30:235–45.

4. Keane PA, Sadda SR. Imaging chorioretinal vascular disease. *Eye*. 2009;24:422–7.
5. Potsaid B, Baumann B, Huang D, *et al*. Ultrahigh speed 1050 nm swept source/Fourier domain OCT retinal and anterior segment imaging at 100,000–400,000 axial scans per second. *Opt Express*. 2010;18:20029–48.
6. Wojtkowski M, Kaluzny B, Zawadzki RJ. New directions in ophthalmic optical coherence tomography. *Optom Vis Sci* 2012 Mar 22.
7. Spaide RF, Koizumi H, Pozzoni MC. Enhanced depth imaging spectral domain optical coherence tomography. *Am J Ophthalmol*. 2008;146:496–500.
8. Podoleanu G., Dobre G.M., Webb D.J., Jackson D.A.. Simultaneous en-face imaging of two layers in the human retina by low-coherence reflectometry. *Opt Lett*. 1997;22 (13):1039–41.
9. Rogers J, Podoleanu A, Dobre G, *et al*. Topography and volume measurements of the optic nerve using en-face optical coherence tomography. *Opt Express*. 2001;9: 533–45.
10. Tao YK, Ehlers JP, Toth CA, Izatt JA. Intraoperative spectral domain optical coherence tomography for vitreoretinal surgery. *Opt Lett*. 2010;35:3315–3317.
11. Regatieri CV, Branchini L, Duker JS. The role of spectral domain OCT in the diagnosis and management of neovascular age related macular degeneration. *Ophthalmic Surg Lasers Imaging*. 2011;42:S56–66.
12. Kocaoglu OP, Lee S, Jonnal RS, *et al*. Imaging cone photoreceptors in three dimensions and in time using ultrahigh resolution optical coherence tomography with adaptive optics. *Biomed Opt Express*. 2011;2:748–63.
13. Klein T, Wieser W, Eigenwillig CM, Biedermann BR, Huber R. Megahertz OCT for ultrawidefield retinal imaging with a 1050 nm Fourier domain modelocked laser. *Opt Express*. 2011;19:3044–6.
14. Povazay B, Hermann B, Hofer B, *et al*. Widefield optical coherence tomography of the choroid in vivo. *Invest Ophthalmol Vis Sci*. 2009;50:1856–63.
15. Zawadzki RJ, Jones SM, Pilli S, *et al*. Integrated adaptive optics optical coherence tomography and adaptive optics scanning laser ophthalmoscope system for simultaneous cellular resolution in vivo retinal imaging. *Biomed Opt Express*. 2011;2:1674–86.
16. Miller DT, Kocaoglu OP, Wang Q, Lee S. Adaptive optics and the eye (super resolution OCT). *Eye (Lond)*. 2011;25:321–30.
17. An L, Subhush HM, Wilson DJ, Wang RK. High-resolution Widefield imaging of retinal and choroidal blood perfusion with optical microangiography. *J Biomed Opt*. 2010;15:026011.
18. Sadda S. Future OCT technology. Paper presented at Macula 2012, New York, NY, January 21, 2012.
19. Wang Y, Lu A, GilFlamer J, Tan O, Izatt JA, Huang D. Measurement of total blood flow in the normal human retina using Doppler Fourier domain optical coherence tomography. *Br J Ophthalmol*. 2009;93:634–7.
20. Michels S, Pircher M, Geitzenauer W, *et al*. Value of polarization-sensitive optical coherence tomography in diseases affecting the retinal pigment epithelium. *Br J Ophthalmol*. 2008;92:204–9.
21. Yamanari M, Lim Y, Makita S, Yasuno Y. Visualization of phase retardation of deep posterior eye by polarization sensitive swept source optical coherence tomography with 1 micron probe. *Opt Express*. 2009;17:12385–96.

**How to cite this article** Mohana KP, Das D, Muna B. Optical Coherence Tomography: Newer Techniques, Newer Machines, *Sci J Med & Vis Res Foun* 2015;XXXIII:75–79.

# Intravitreal Injection Guidelines

Ekta Rishi and Pramod Bhende

Shri Bhagwan Mahavir  
Vitreoretinal Services,  
Sankara Nethralaya

**Correspondence to:**  
Ekta Rishi,  
Senior Consultant,  
Shri Bhagwan Mahavir  
Vitreoretinal Services,  
Sankara Nethralaya.  
E-mail: drepr@snmail.org

With an increase in the number of intravitreal injections especially intravitreal anti-vascular endothelial growth factor (anti-VEGF) agents the risk for endophthalmitis is a potential concern.

A meta-analysis by Jager et al.<sup>1</sup> shows that the prevalence of endophthalmitis following intravitreal injections is low. They evaluated the incidence of endophthalmitis into infectious and non-infectious categories and found that the endophthalmitis rate was 0.9% (38/4382) per eye and 0.3% (38/14 866) per injection, when looking at both infectious and non-infectious cases. They also found endophthalmitis rate of 1.4% per injection for intravitreal triamcinolone acetonide and 0.2% per injection for intravitreal ranibizumab.

The risk of endophthalmitis after intravitreal injection may vary with various drugs.<sup>2</sup> The reported incidence of endophthalmitis per patient in multi-center clinical trials with anti-vascular endothelial growth factor (VEGF) therapy ranged from 0.019 to 1.6%.<sup>2-4</sup> Although cases of acute endophthalmitis following intravitreal bevacizumab (IVB) have occurred, the exact incidence rate remains unknown. The injection technique and compounding issues of bevacizumab remains the major areas of concern. Ranibizumab comes as a single use vial so the concerns are limited to injection techniques.

These guidelines are framed to reduce the risk of endophthalmitis by streamlining the compounding and injection techniques with special reference to bevacizumab.

The risk for endophthalmitis following Intravitreal Injections could be:

- 1 Drug related:
  - a Counterfeit medication
  - b Lapse in cold chain
- 2 Procedure related
  - a Multiple use of multi-dose vial
  - b Injection technique
  - c Aseptic precautions

## Drug related

This concern is more with off label drugs like bevacizumab.

### Counterfeit medication

There are reports of counterfeit medications across the world for bevacizumab. In 2010–11, the concern was raised in China and the USA.<sup>5</sup>

How to address and make sure that the drug is not fake?

- 1 Check the authorization letter of the bevacizumab dealer and buy the drug from a certified Roche dealer. Since the use in the eye is off label, the dealers may not have the authorization for supply to the ophthalmologists. We can inspect the authorization and bills from Roche periodically.
- 2 Check the drug license of the dealer.

### Cold chain lapse

Bevacizumab can be stored at 2–8°C for 45 days. Roche monitors the cold chain on its server till it transports to the authorized dealer. The company also monitors and maintains a log of cold chain at the storage facility of the dealer.

Our suggestions

- Inspect the cold chain maintenance of the dealer.
- Verify that the drug has not been kept in stock for a long period.
- Check how long does the dealer stocks the drug.

### Storage

Once purchased, check that the drug is brought in a dry ice pack preferably with a temperature monitoring device.

It should be stored at the hospital refrigerator at 2–8°C in a dark place with temperature display, power backup, and a temperature log. Electronic data loggers are available in the market to monitor the temperature.

The drug should be kept under lock so that limited people have the access to it and refrigerator is not opened again and again to avoid a lapse in cold chain.

### Injection procedure related

How to use the multi-dose vial of 4 ml?

The study by Bakri et al. shows that the drug can be kept in capped disposable 1 ml syringes when stored at 2–8°C with minimal loss of efficacy over 1 month, but there is no level 1 evidence for sterility.<sup>6</sup> There are published articles for compounding the drug in aliquots for multiple use but there are reports of endophthalmitis resulting from compounding issues.

We suggest opening a vial and preparing the required number of injections under sterile conditions and storing in different sterile boxes to be used within few hours if it has to be used by

different surgeons in different operation theatres on the same day within the same theatre complex. One box can be sent to each operation theatre with the required number of filled syringes.

It is preferred to do the injection procedure in operation theater or a sterile room designated for such procedures.<sup>7,8</sup>

#### Preparation of multiple syringes for use on a given day

- Note the batch number of the drug so that it can be helpful for tracking, in case of endophthalmitis.
- To check the bevacizumab vial for expiry date and label by the technician.
- Opening of the vial and cleaning of rubber lid by alcohol wipes.
- 18/20 G needle is inserted in the rubber lid of vial by a scrubbed paramedical staff in the operation theatre with mask and cap with minimal talking. Instead of using the 18/20G needle for puncture an instrument called mini-spike (Braun) can be used to prepare multiple syringes to avoid contamination.
- The vial must be held upside down by non-scrubbed personnel in the operation theater wearing a cap and mask
- The scrubbed staff can withdraw 0.2 cc of bevacizumab in a 1 cc disposable syringe and cap it with the needle.
- Prepare the number of injections required for the day by withdrawing drug from a single puncture by 18/20G needle.
- The prepared capped syringes with the drug can be stored in separate boxes depending on the number of surgeons giving the injection on the given day. The boxes can be kept in a refrigerator maintained at 2–8°C and should be used on the same day.
- One syringe can be sent for bacterial culture sensitivity testing so that on follow-up of these patients the report can help us to decide the next plan of action in case of infection.
- Preparation of similar aliquots in a sterile environment under a laminar hood is also described.

#### Injection technique

- The literature suggests that prophylactic antibiotics are not better than the use of povidone iodine 5% drops for a contact period of 5 minutes in the conjunctival cul-de-sac.<sup>9–12</sup>
- Patients with doubtful hygiene, one eyed and with known povidone allergy, can have either

3 days of topical fluoroquinolones or pulse dose of fluoroquinolone eye drops on the same day of injection.

- We suggest that the injector has a proper scrub wears disposable mask, and gloves. If in operation theatre, cap is mandatory.
- The eye lids and lashes should be scrubbed with 10% povidone iodine solution and eye should be draped.
- Lid speculum should be used to avoid the contact of eye lashes with the injection site. Use of lid speculum is reported to reduce the risk of endophthalmitis in the intravitreal injection procedure. Contact of the needle with eyelashes should be avoided.<sup>13–15</sup>
- Injection can be administered after the use of sterile proparacaine eye drops.
- The needle used to cap the drug syringe for storage should be replaced by a 30G needle for injection.<sup>16</sup>
- Oblique scleral entry is preferred over perpendicular injection to prevent reflux of vitreous and wick related endophthalmitis.<sup>16–19</sup>
- Any quadrant can be chosen for injection (infero-temporal quadrant is preferred, particularly for opaque drugs which otherwise can cause significant visual disturbance, e.g. triamcinolone). Sterile calipers can be used to measure 3–4 mm from limbus (depending on lens status) to mark the injection site.
- Usage of mask is a must. Avoid talking while giving the injection. Gram-positive cocci are the commonest infections following intravitreal injections and droplet infection may be the source.<sup>12,20,21</sup>
- The eye can be patched with povidone iodine 5% drops for 2 hours after injection.
- Patients should be examined on post injection day 1 and 3. We suggest a good examination of anterior segment using slit lamp and fundus using indirect ophthalmoscopy. Also check intraocular pressure using Applanation tonometry. It is preferable to see the patient on the third post injection day as most of the endophthalmitis after bevacizumab have occurred between 2 and 5 days.
- Patients should be instructed to avoid head bath for 1 day post injection and swimming for 3 days post injection.
- Post injection antibiotic prophylaxis should be reserved for one-eyed patients and patients with doubtful hygiene or with iodine allergy. Most of the studies suggest no role of antibiotics in post injection period.

- In case the patient is due for injection in both eyes, it should be done at an interval of 3 days to avoid an increased level of circulating drug in the system. Some studies suggest that separate batch number of the vials may be used for the two eyes in case bilateral injections are required on the same day.
- Anti-VEGF injections should be deferred in pregnant ladies or people with uncontrolled hypertension or increased risk of thromboembolic phenomenon or recent history of stroke or myocardial infarction.
- Injections should be avoided in people with uncontrolled blood sugar levels as it may in turn increase the chances of endophthalmitis.

#### Discarding the unused drug

It is preferable to discard the unused drug and destroy the label.

The bottle can be discarded as per the norms.

#### References

1. Jager RD, Aiello LP, Patel SC, Cunningham ET Jr. Risks of intravitreal injection: a comprehensive review. *Retina*. 2004;24:676-98.
2. Scott IU, Flynn HW Jr. Reducing the risk of endophthalmitis following intravitreal injections. *Retina*. 2007;27:10-12.
3. Rosenfeld PJ, Brown DM, Heier JS, Boyer DS, Kaiser PK, Chung CY, Kim RY, for the MARINA Study Group. Ranibizumab for neovascular age-related macular degeneration. *N Engl J Med*. 2006;355:1419-31.
4. Brown DM, Kaiser PK, Michels M, Soubrane G, Heier JS, Kim RY, Sy JP, Schneider S, for the ANCHOR Study Group. Ranibizumab versus verteporfin for neovascular age-related macular degeneration. *N Engl J Med*. 2006;355:1432-44.
5. Wyckoff CC, Flynn HW Jr, Rosenfeld PJ. Prophylaxis for endophthalmitis following intravitreal injection: antisepsis and antibiotics. *Am J Ophthalmol*. 2011;152(5):717-9.
6. Bakri SJ, Synder MR, Pulido JS, McCannel CA, Weiss WT, Singh RJ. Six month stability of Bevacizumab (Avastin) binding to vascular endothelial growth factor after withdrawal into a syringe and refrigeration or freezing. *Retina*. 2006;26:519-22.
7. Casparis H, Wolfensberger TJ, Becker M, Eich G, Graf N, Ambresin A, Mantel I, Michels S. Incidence of presumed endophthalmitis after intravitreal injection performed in the operating room: a retrospective multicenter study. *Retina*. 2014;34(1):12-7.
8. Abell RG, Kerr NM, Allen P, Vote BJ. Intravitreal injections: is there benefit for a theatre setting? *Br J Ophthalmol*. 2012;96(12):1474-8.
9. Cheung CY, Wong AT, Lui A, Kertes PJ, Devenyi RG, Lam WC. Incidence of endophthalmitis and use of antibiotic prophylaxis after intravitreal injections. *Ophthalmology*. 2012;119(8):1609-13.
10. Kim SJ, Toma HS. Ophthalmic antibiotics and antimicrobial resistance: a randomized, controlled study of patients undergoing intravitreal injections. *Ophthalmology*. 2011;118:1358-63.
11. Bhat SB, Stepien KM, Joshi K. Prophylactic antibiotic use after intravitreal injection: effect on endophthalmitis rate. *Retina*. 2011;31:2032-6.
12. Moss JM, Sanislo SR, Ta CN. A prospective randomized evaluation of topical gatifloxacin on conjunctival flora in patients undergoing intravitreal injections. *Ophthalmology*. 2009;116:1498-501.
13. Green-Simms AE, Ekdawi NS, Bakri SJ. Survey of intravitreal injection techniques among retinal specialists in the United States. *Am J Ophthalmol*. 2011;151(2):329-32.
14. Fineman MS, Hsu J, Spirm MJ, Kaiser RS. Bimanual assisted eyelid retraction technique for intravitreal injections. *Retina*. 2013;33(9):1968-70.
15. Ratnarajan G, Nath R, Appaswamy S, Watson SL. Intravitreal injections using a novel conjunctival mould: a comparison with a conventional technique. *Br J Ophthalmol* 2013;97(4):395-7.
16. Rodrigues EB, Grumann A Jr, Penha FM, Shiroma H, Rossi E, Meyer CH, Stefano V, Maia M, Magalhaes O Jr, Farah ME. Effect of needle type and injection technique on pain level and vitreal reflux in intravitreal injection. *J Ocul Pharmacol Ther* 2011;27(2):197-203.
17. Rodrigues EB, Meyer CH, Grumann A Jr, Shiroma H, Aguni JS, Farah ME. Tunnelled scleral incision to prevent vitreal reflux after intravitreal injection. *Am J Ophthalmol*. 2007;143(6):1035-7.
18. Knecht PB, Michels S, Sturm V, Bosch MM, Menke MN. Tunnelled versus straight intravitreal injection: intraocular pressure changes, vitreous reflux, and patient discomfort. *Retina*. 2009;29(8):1175-81.
19. De Stefano VS, Abechain JJ, de Almeida LF, Verginassi DM, Rodrigues EB, Freymuller E, Maia M, Magalhaes O, Nguyen QD, Farah ME. Experimental investigation of needles, syringes and techniques for intravitreal injections. *Clin Experiment Ophthalmol*. 2011;39(3):236-42.
20. McCannel CA. Meta-analysis of endophthalmitis after intravitreal injection of anti-vascular endothelial growth factor agents: causative organisms and possible prevention strategies. *Retina*. 2011;31(4):654-61.
21. Wen JC, McCannel CA, Mochon AB, Garner OB. Bacterial dispersal associated with speech in the setting of intravitreal injections. *Arch Ophthalmol*. 2011;129(12):1551-4.

**How to cite this article** Rishi E, Bhende P. Intravitreal Injection Guidelines, *Sci J Med & Vis Res Foun* 2015; XXXIII:80-82.

## Recent Advancements in Ocular Electrodiagnostics

Parveen Sen and Ramya Sachidanandam

Sri Bhagwan Mahavir  
Vitreoretinal Services,  
Sankara Nethralaya

**Correspondence to:** Parveen Sen,  
Senior Consultant,  
Sri Bhagwan Mahavir  
Vitreoretinal Services,  
Sankara Nethralaya.  
E-mail: drpka@snmail.org

Electrophysiology of the eye is a non-invasive method that allows functional assessment of retina as well as the whole visual pathway. Although there are many electrophysiological tests for assessing function of retina and visual pathway, the following protocols play a major role in the diagnosis and management of retinal disorders.

- 1 Full-field electroretinogram (ffERG).
- 2 Visual evoked potential (VEP)
- 3 Electrooculogram (EOG).
- 4 Multifocal electroretinogram (mfERG).
- 5 Multifocal visual evoked potential (mfVEP).
- 6 Pattern electroretinogram (PERG).
- 7 Photopic negative response (PhNR).
- 8 Sweep VEP (sVEP)

International Society of Clinical Electrophysiology of Vision (ISCEV) has set standards for recording each one of these tests except for photopic negative response and sweep VEP.

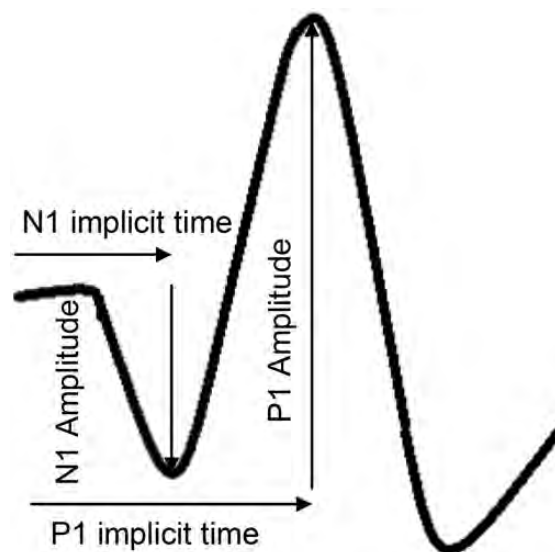
### Multifocal electroretinogram (mfERG)

Where ffERG is a mass electrical response generated by retinal cells in response to a flash of light, mfERG stimulates various focal areas of the retina and picks up focal disease as well as maps the disease distribution. MfERG was developed by Erich Sutter.<sup>1</sup> It is recorded monocularly using

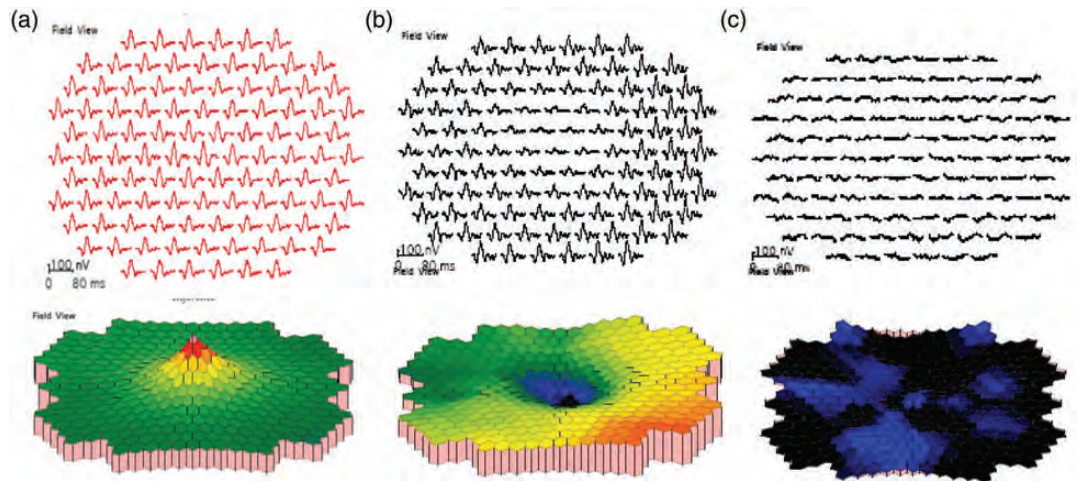
Burian Allen electrodes in a light adapted state after pupillary dilatation with refractive error correction in place. Since testing is done in a light-adapted state, the mfERG responses are primarily cone driven. It evaluates the function of fovea, parafovea and perifovea using 103 alternating white and black hexagons.

A typical mfERG waveform of the first-order kernel consists of an initial negative wave (N1) followed by a positive peak (P1) (Fig. 1). These appear similar to the ffERG photopic 'a wave' and 'b wave', but they are not identical.

The data are displayed in the form of three-dimensional topographic plots, group averages or trace arrays. Group averages and topographic plot evaluate the distribution of retinal signal. The three-dimensional plots should be seen with corresponding mfERG trace arrays for an accurate interpretation of results. Since mfERG is easy to interpret and well tolerated by the patient, it is extensively used in various hereditary retinal disorders. In congenital maculopathies like Stargardt's macular dystrophy and Vitelliform macular dystrophy (VMD), the foveal responses on mfERG are markedly diminished surrounded by near-normal perifoveal responses. In contrast in cone dystrophies, the mfERG-responses across the entire retina are markedly decreased or lost (Fig. 2). Role of mfERG in early stages of retinotoxicity due to various drugs such as chloroquine, hydroxychloroquine, deferoxamine and ethambutol is vital.<sup>2</sup> It is now an integral part of



**Fig. 1.** Normal waveform of multifocal ERG.



**Fig. 2.** mfERG trace array and 3-D plot multiplot (a) normal mfERG (b) Stargadt's disease showing reduced foveal and parafoveal ring responses with normal perifoveal ring responses (c) Cone dystrophy showing generalized reduction of responses.

the new standard protocol for diagnosis of retinal toxicity secondary to these drugs. MfERG can also be used as a tool for post treatment follow-up of patients with choroidal neovascular membrane or macular hole.

MfERG plays little role in optic nerve disorders because the ganglion cells do not contribute to it.

#### Multifocal visual evoked potential (mfVEP)

Flash and pattern VEP evaluate the optic nerve function. Flash VEP is mass response and pattern VEP is dominated by responses from macular area. The mfVEP as developed by Baseler et al.<sup>3</sup> measures VEP responses from the focal areas of the visual field and helps in picking up distribution of the optic nerve dysfunction. Interocular comparison of mfVEP recordings is a sensitive indicator of optic nerve disease (Fig. 3). MfVEP can also be done in subjects not cooperative for visual field testing and in children.


#### Photopic negative response (PhNR)

In addition to pattern VEP, PhNR has been used as an indicator for ganglion cell function

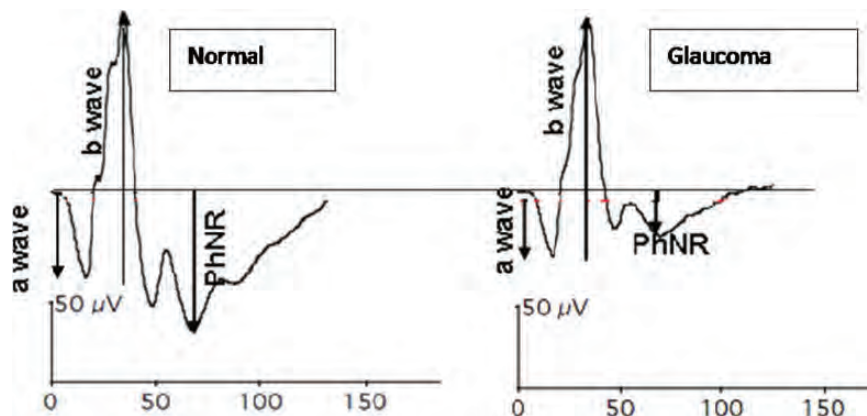
especially in early glaucomatous neuropathy.<sup>4</sup> The PhNR is a slow negative potential that is seen after the b-wave of a light-adapted ffERG. The background illumination and the stimulus color are altered in the basic ffERG protocol to record PhNR. It can be recorded as full-field PhNR, focal PhNR and multifocal PhNR. The full-field PhNR reflects the overall retinal ganglion cell function and is used to assess the generalized optic nerve damage while focal PhNR can reflect early damage.<sup>4</sup> The PhNR is found to be decreased in primary open-angle glaucoma Fig. 4, ocular hypertension and diabetic retinopathy. The PhNR amplitudes for red stimulus on blue background are large and are more effective in identifying early glaucomatous damage.<sup>5</sup>

#### Pattern Electroretinogram (PERG)

PERG is helpful to differentiate between optic nerve disease and macular disorder.<sup>6</sup> Transient PERG is produced by alternating reversal of a black and white checkerboard pattern at a reversal rate of 6 per second. Normal transient PERG has two main components: P50 (positive component appearing at



**Fig. 3.** MfVEP responses of 48-year-old female with pituitary adenoma and bitemporal hemianopia in HVF 30-2 showing bilateral non-recordable temporal waveforms.



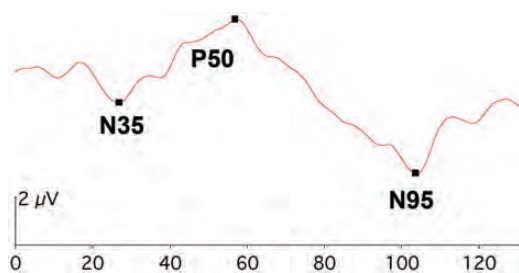
**Fig. 4.** The amplitude of PhNR (photopic negative response) is reduced in a glaucomatous (b) eye as compared to a normal waveform (a).

45–60 ms) which shows macular function and N95 (larger negative component appearing at 90–100 ms) which shows ganglion cell function (Fig. 5). PERG has very low amplitude (0.5–8 µV); special care is needed to differentiate it from noise during recording.

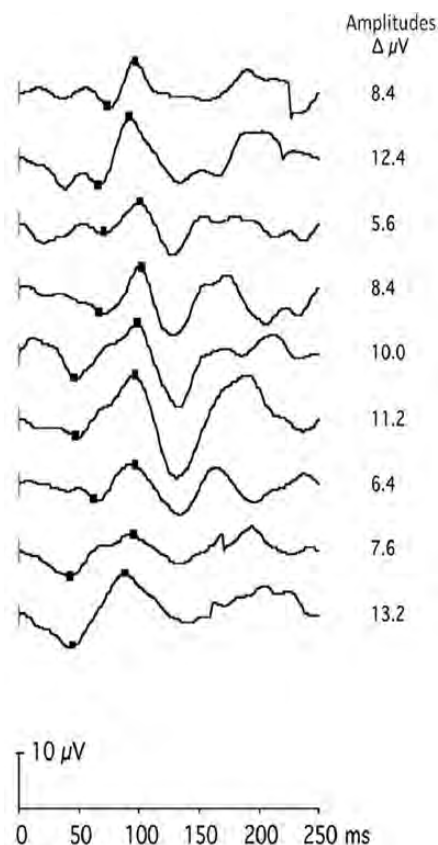
It is recorded binocularly using the DTL electrodes without pupillary dilatation with refractive error correction in place. Normal fFERG with decrease in P50 amplitude depicts localized macular dysfunction as seen in patients with Stargadt’s disease, macular hole and age related macular degeneration. An abnormal fFERG with an abnormal PERG suggests a generalized retinal disorder as is evident in cone rod dysfunction with macular involvement. Selective reduction of N95 component, with a near normal P50 wave suggests optic nerve pathology. N95/P50 ratio remains normal in macular disease but decreases in optic nerve diseases. During acute phase of optic neuritis a profound loss of visual acuity is seen with non-recordable PERG waveforms. In chronic phase of optic neuritis as the optic nerve edema resolves P50 recovers while N95 remains abnormal with significant reduction in the N95: P50 ratio. This is because of the retrograde degeneration of the ganglion cells seen in the chronic stages of optic neuritis.<sup>7</sup> Although PERG can differentiate between a retinal and an optic nerve

disorder it does not give us the topography of the disease process.

Hence, a combination of these new investigation modalities can give us a better understanding of the physiology of the various ocular diseases and help in their management.



**Fig. 5.** Normal waveform of PERG showing N35, P50 and N95 components.



**Fig. 6.** Sweep VEP of nine different spatial frequencies. The calculated Minimal angle of resolution (MAR) based on amplitude values for different spatial frequencies (ranging from 3 to 32 cycles/degree) is 0.360 and the Snellen visual acuity is 6/13.4.



### Sweep visual evoked potentials (sVEP)

The sVEP was introduced by Regan D (1973) for measuring refractive error objectively.<sup>8</sup> It evaluates the visual acuity in infants, non-verbal and uncooperative children objectively.<sup>9</sup> The sVEP has many spatial frequencies that are swept in single recording session within 10–15 s of duration (Fig. 6). By sweeping the spatial frequency from high to low, the visual acuity is obtained by determining the highest spatial frequency to which the visual system responds.<sup>10</sup>

### Conclusion

Various electrophysiological tests help in arriving at diagnosis and few tests help in the management of certain ocular diseases. mfERG assess retinal function in various retinal locations, mfVEP assess focal areas of visual pathway function, PERG help in differentiating retinal and optic nerve disorders, PhNR helps to assess ganglion cell function and sVEP is a objective quick method to quantify visual acuity.

### References

1. Sutter E. Imaging visual function with the multifocal m-sequence technique. *Vision Res.* 2001;41:1241–55.
2. Maturi RK, Yu M, Weleber RG. Multifocal electroretinographic evaluation of long-term hydroxychloroquine users. *Arch Ophthalmol.* 2004;122(7):973–81.
3. Baseler HA, Sutter EE, Klein SA, Carney T. The topography of visual evoked response properties across the visual field. *Electroencephalogr Clin Neurophysiol.* 1994;90:65–81.
4. Viswanathan S, Frishman L, Robson JG, Walters JW. The photopic negative response of the flash electroretinogram in primary open angle glaucoma. *Invest Ophthalmol Vis Sci.* 2001;42:514–22.
5. Rangaswamy NV, Shirato S, Kaneko M, Digby BI, Robson JG, Frishman LJ. Effects of spectral characteristics of Ganzfeld stimuli on the photopic negative response (PhNR) of the ERG. *Invest Ophthalmol Vis Sci.* 2007;48:4818–28.
6. Bach M, Brigell MG, Hawlina M, Holder GE, Johnson MA, McCulloch DL, Meigen T, Viswanathan S. ISCEV standard for clinical pattern electroretinography (PERG) – 2012 update. *Doc Ophthalmol.* 2013;126:1–7.
7. Holder GE. The incidence of abnormal pattern electroretinography in optic nerve demyelination. *Electroenceph Clin Neurophysiol* 1991;78:18–26.
8. Regan D. Rapid objective refraction using evoked brain potentials. *Invest Ophthalmol Vis Sci.* 1973;12(9):669–79.
9. Tyler CW, Apkarian P, Levi DM, Nakayama K. Rapid assessment of visual function: an electronic sweep technique for the pattern visual evoked potential. *Invest Ophthalmol Vis Sci.* 1979;18:703–13.
10. Zhou P, Zhao MW, Li XX, Hu XF, Wu X, Niu LJ, Yu WZ, Xu XL. A new method for extrapolating the sweep pattern visual evoked potential acuity. *Doc Ophthalmol.* 2007;117(2):85–91.

**How to cite this article** Parveen S, Ramya S. Recent Advancements in Ocular Electrodiagnostics, *Sci J Med & Vis Res Foun* 2015;XXXIII:83–86.

# Genetic Testing for Eye Diseases

Vikas Khetan

Sri Bhagwan Mahavir  
Vitreoretinal Services,  
Sankara Nethralaya

**Correspondence to:**  
Vikas Khetan,  
Senior Consultant,  
Sri Bhagwan Mahavir  
Vitreoretinal Services,  
Sankara Nethralaya.  
Email: drvksnmail.org

Advances in ocular genetic research allows a better understanding of the genetic basis of many eye diseases. Genetic testing is becoming available for more and more disorders and the number of genes being discovered is also on the rise, although the testing may not be accessible to all because of the costs involved.

Finding the genetic basis for a patient's disease allows for risk prediction, accurate diagnosis, focused treatment and preventive screening and care. Personalized medicine, particularly in the field of pharmacogenetics, is becoming a reality and we may be able to offer treatments to patients based on the genetic testing results. We do know that some patients respond and some do not to the same anti-VEGF treatment for AMD/ PCV and part of this could be because of the genetic makeup, therefore if we have the results with us before the start of the treatment, we may be able to decide better for the patient. However, genetic testing for AMD is still in its infancy.

With better understanding of retinal degenerations, we now know that patients with ABCA4 mutations should not be given Vitamin A prophylaxis as it can worsen their disease. So with this knowledge the older practice of putting RP patients on vitamin A prophylaxis has reduced. Whilst there is no effective therapy that we can offer to these patients, we should not cause a further decline in their visual status.

Gene therapy trials have taken place for RPE 65 gene and for choroderemia and more trials are in early phases.

Genotype–phenotype correlation for a few conditions have made us understand the diseases much better. Knowing that a child with aniridia has WAGR syndrome, we can be more vigilant in systemic work up.

Importance of genetic testing for Retinoblastoma cannot be overemphasized. Children with germline mutation are at risk for developing second non-ocular cancers and can also pass the defective mutation to the offspring and this could be explained to the family. For non-germline cases we can avoid unnecessary anesthesia exams. This can also be a big cost saving for the family and can avoid unnecessary long travels to specialized centers.

At Sankara Nethralaya, we have now started offering genetic testing for a lot of eye conditions after a pedigree-based counseling and the results are then handed over to the patient after proper verification. The whole process takes around 4–6 months.

I would recommend all readers to read the article by Ed Stone et al. in ophthalmology about recommendations for genetic testing of inherited eye diseases.

## Reference

Stone EM, Aldave AJ, Drack AV, Maccumber MW, Sheffield VC, Traboulsi E, Weleber RG. Recommendations for genetic testing of inherited eye diseases: report of the American Academy of Ophthalmology task force on genetic testing. *Ophthalmology* 2012;119(11):2408–10.

**How to cite this article** Vikas K. Genetic Testing for Eye Diseases, *Sci J Med & Vis Res Foun* 2015;XXXIII:87.

# Update on Intraocular Oncology

Suganeswari Ganesan

Shri Bhagwan Mahavir  
Vitreoretinal Services,  
Sankara Nethralaya

**Correspondence to:**  
Suganeswari Ganesan,  
Consultant,  
Vitreoretinal and Oncology  
services,  
Sankara Nethralaya.  
E-mail: drgsi@snmail.org

## Introduction

Ocular oncology has been evolving with new imaging techniques and treatment modalities. Imaging techniques have revolutionized the understanding of the basic concepts of the tumor pathology and have provided insights into the development of newer modalities of treatment. In the practice of Oncology, the primary focus has always been to save the life of the individual suffering from any carcinoma and this was also true for intraocular tumors with practicing ophthalmologist needing to perform enucleation for most of the intraocular tumors like the retinoblastoma in the children and choroidal melanoma in adults. With developments in ophthalmology and with changing trends in diagnostic and management modalities, the attention has shifted from purely saving the lives to improving the quality of life. The quest to improve the quality of life in cancer survivors has led to the discovery of new techniques that can salvage the eye and the vision while simultaneously destroying the cancer tissue. In the most common pediatric cancer, the retinoblastoma the survival rates are nearly 100%. The success rates as per the International Classification of Retinoblastoma with standard intravenous chemotherapy in group A (100%), B (93%), C (90%), D (48%), and E (25%).<sup>1</sup> The eye salvage in retinoblastoma is achieved through the delivery of chemotherapy in various routes like the intravenous, intra-arterial and intravitreal routes and the localized radiation therapy called the brachytherapy. In the management of choroidal melanoma, brachytherapy plays a vital role in tumor regression and also produces equivocal results when compared with enucleation (removal of the eye) in prevention of metastatic melanoma which was made evident by the Collaborative Ocular Melanoma Study (COMS), conducted over a period of 12 years. In the past three decades, we have seen a revolution in conservative therapy with early detection of melanoma when the tumor is 1–2 mm in thickness rather than detecting at 8–10 mm. In this update on intraocular oncology, we shall be discussing about some of the eye-sparing techniques like brachytherapy, intra-arterial chemotherapy and intravitreal chemotherapy.

## Ophthalmic brachytherapy

### Definition

Brachytherapy (brachys, meaning ‘short-distance’) is also known as internal radiotherapy. It found its use in ophthalmology in the year 1930. Ophthalmic brachytherapy is a surgical procedure

wherein localized radiation is delivered to the base of the intraocular tumor by surgically anchoring a radioactive-loaded plaque over the scleral surface. Plaque brachytherapy has evolved as an excellent alternative technique to enucleation sparing both eye and vision.

## Intraocular tumors treated by brachytherapy with recommended doses<sup>2</sup>

Choroidal melanoma: 85 Gy  
Retinoblastoma: 40 Gy  
Vasoproliferative tumors: 40 Gy  
Choroidal hemangioma: 40 Gy

## Brachytherapy team

Plaque surgeon  
Radiation oncologist  
Medical physicist

## Commonly used isotopes in brachytherapy


Ruthenium (Ru)-106  
Palladium (Pd)-103  
Iodine (I)-125  
Strontium-90 (<sup>90</sup>Sr)

Photon	Decay	Half life (days)
<sup>125</sup> I	Gamma	59.4
<sup>103</sup> Pd	Gamma	16.99
<sup>131</sup> Cs	Gamma	9.69
<sup>106</sup> Ru	Beta	371.8
<sup>90</sup> Sr	Beta	28.8


Dose calculation is done using the plaque simulator software version (Bebig GmbH, Berlin, Germany). The longitudinal, circumferential and apical diameters of the tumor are important parameters to be measured using ultrasonography.

## Structure of Indian plaque

Indian plaque is manufactured by Bhabha Atomic Research Center called ‘BARC I-125 Ocu-Prosta seeds’. Radioiodine (<sup>125</sup>I) adsorbed on palladium-coated silver rod encapsulated by titanium capsule.<sup>3</sup> Slotted, unslotted, rimmed, unrimmed gold plaques are available. COMS plaques are circular rimmed plaques.



**Fig. 1.** Unslotted gold plaque in different sizes.



**Fig. 2.** BARC  $^{125}\text{I}$  Ocu-Prosta seeds.



**Fig. 3.** Plaque with the glued BARC  $^{125}\text{I}$  Ocu-Prosta seeds.

#### Technique

##### *Placement of plaque*

It is performed under peribulbar or retrobulbar anesthesia for adult patients and under general anesthesia for children. After cleaning, prepping and draping of the involved eye, localized peritomy is made in the involved quadrant. Tagging of the rectus muscle is done. Localization of the tumor is done with transillumination or scleral

depression. Plaque containing the seeds is anchored to sclera. Conjunctiva is closed with sutures. Eye should be covered with lead shield and patient to be kept in isolation for a period of 4–5 days depending on the dosimetry.

##### *Removal of plaque*

It is also performed under aseptic precautions as described above. Localized peritomy is made in the involved quadrant. Anchoring sutures are cut. Plaque is removed with seeds in to. Seeds have to be counted and checked. Conjunctiva is closed with sutures. The radioactive seeds are returned back to Bhabha Atomic Research Center.

#### Limitations in choroidal melanoma

- Tumor more than 12 mm in apical height or 20 mm in basal diameter.<sup>4</sup>
- Gross extraocular extension.
- Painful blind eyes.
- Eyes with no perception of light.

#### Complications of brachytherapy<sup>5</sup>

- Radiation cataract.
- Radiation retinopathy.
- Radiation optic neuropathy.

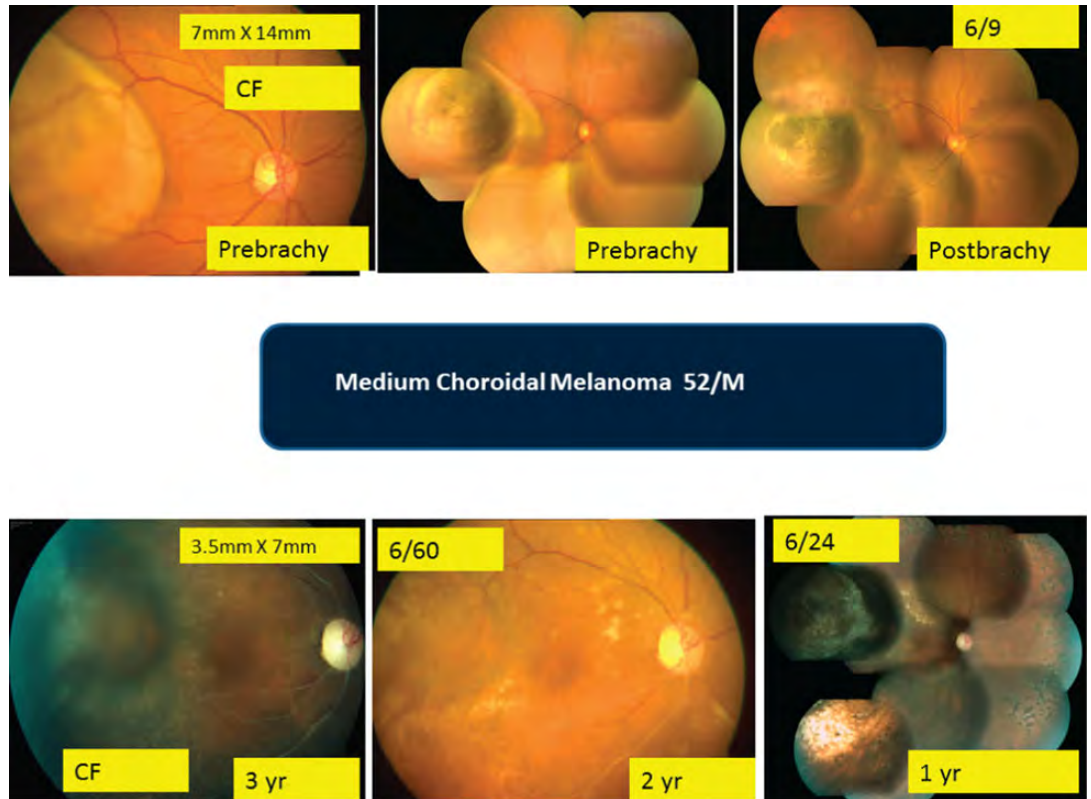
#### Intra-arterial chemotherapy (IAC)

##### Definition

Intra-arterial chemotherapy is a targeted therapy against retinoblastoma that involves the delivery of potent chemotherapy directly into the ophthalmic artery.

##### Evolution

The first initiative was made in 1954 by Reese et al.<sup>6</sup> In 1966, Kiribuchi shared his success story with injection of 5-fluorouracil into the frontal or supraorbital artery of children with retinoblastoma.<sup>7</sup> The technique of IAC has evolved over the past 15 years with Japanese investigators showing success with delivery of melphalan into the ophthalmic artery by occluding distal flow in the internal carotid artery using catheterization and



**Fig. 4.** The pre- and post-brachytherapy of a medium sized choroidal melanoma with features of radiation retinopathy at 2 years.

balloon occlusion.<sup>8,9</sup> Gobin and Abramson of the USA refined further by cannulating the proximal ophthalmic artery precisely under fluoroscopic guidance for chemotherapy to perfuse the eye selectively without perfusing the brain.<sup>10</sup>

#### Team

Ocular oncologist, endovascular neurosurgeon, pediatric oncologist

#### Japanese technique

The Japanese technique was called selective ophthalmic arterial infusion (SOAI) therapy. The SOAI system consists of a micro-balloon, guiding catheter and a flushing hub. After selective catheterization to the cervical segment of the internal carotid artery by the guiding catheter, the micro-balloon was propelled to the portion just distal to the orifice of the ophthalmic artery. During temporary occlusion of the internal carotid artery, melphalan was infused from the introduced catheter tip.<sup>11</sup>

#### American technique

Performed under general anesthesia with anticoagulation [intravenous heparin (75 IU/kg)] in the operation theatre. Femoral region is cleaned, draped and 4-French arterial sheath is placed. The catheter is guided into the ipsilateral internal

carotid artery using fluoroscopic guidance. Serial arteriogram is done for deciding the best approach. Ipsilateral proximal portion of the ophthalmic artery is catheterized with a microcatheter and a confirmatory angiogram is then performed. Chemotherapy is diluted in 30 ml of saline is delivered using a pulsatile, non-laminated technique manually over 30 min. Once the infusion is completed, a post-infusion arteriogram is done. The catheters are withdrawn and the femoral sheath is removed. By manual compression the hemostasis of the femoral artery is achieved. Child is kept on oral aspirin (40 mg) for 2 weeks.<sup>12</sup>

#### Dosage

- Melphalan: starting at 2.5 mg for 3 months to 5.0 mg for a 3 years
- Topotecan: starting at 0.3 mg for 3 months to 0.4 mg for a 3 years
- Carboplatin: 30 mg for 6 months to 3 years

#### Eyes that would benefit from IAC

- Primary IAC: International Classification of Retinoblastoma (group C, group D and group E)
- Secondary IAC: other modalities have failed

**Eyes that should not be considered for IAC**

- Possibility of tumor regression with focal therapy (laser/trans pupillary thermotherapy/cryotherapy)
- Possibility of tumor regression with brachytherapy
- Possibility of tumor regression with intravenous chemotherapy
- Neovascular glaucoma
- Presence of invasion into the optic nerve
- Presence of invasion into the choroid
- Presence of extrascleral extension
- Anaphylactic reaction with previous IAC
- Poor visualization of the tumor
- Persistent retinal detachment

**Complications from IAC<sup>12</sup>**

- Ophthalmic artery stenosis
- Occlusion of central retinal artery/ branch retinal artery occlusion/ciliary arteries
- Orbital vascular occlusion
- Eyelid edema
- Blepharoptosis
- Cilia loss
- Orbital congestion
- Temporary extraocular dysmotility
- Retinal pigment epithelial mottling
- Radiation-related toxic effects

**Concern**

- Anomalous origin of the ophthalmic artery
- Blood dyscrasia

**Intravitreal injections in intraocular oncology****Definition**

Intravitreal chemotherapy is a targeted therapy against retinoblastoma seeds in the vitreous that involves the delivery of potent chemotherapy directly into the vitreous.

**Evolution**

Ericson et al.<sup>13</sup> were the first to initiate the intravitreal chemotherapy for retinoblastoma in the year 1960. The superior efficacy of melphalan was established by Inomata and Kaneko.<sup>14</sup> Later, Kaneko presented his unpublished data on achieving eye salvage rate of 51% by treating 41 eyes

with intravitreal injection of 8–30 µg melphalan and ocular hyperthermia for vitreous seeds. Since then melphalan hydrochloride, topotecan hydrochloride and methotrexate have been in use.

**Team**

Ocular oncologist, anesthetist and pediatric oncologist.

**Dosage**

20–40 µg of melphalanhydrochloride<sup>15</sup>  
8–20 µg of topotecan hydrochloride<sup>15</sup>

**Technique**

It is performed under general anesthesia after cleaning and draping of the involved eye using a sterile technique. Melphalan is available as a freeze-dried powder is prepared using the provided sterile diluent with concentration of 20 µg/0.1 ml. The half-life is ~90 min. Injected through the pars plana (3 mm from limbus, beveled approach) with a 30 G needle 1–2 clock hours away from the vitreous seed cryotherapy is applied to the injection site to include the needle in the ice ball withdrawing the needle through the ice ball during the first freeze. Triple freeze thaw cryotherapy is then completed. The eyeball should be moved with forceps vigorously to cause drug dispersion throughout the vitreous cavity and preferably to the site of vitreous seeds.

**Eyes that would benefit**

Persistent/recurrent/viable vitreous retinoblastoma seeds with good regression of the solid tumor.<sup>16</sup>

**Eyes that should not be considered for intravitreal chemotherapy**

- Presence of viable solid intraretinal retinoblastoma
- Presence of viable viable subretinal seeds
- Presence of uveal or optic nerve invasion
- Risk for metastatic disease

**Complications**

- Focal retinal pigment epithelial mottling
- Risk for extraocular subconjunctival extension
- Vitreous hemorrhage
- Retinal detachment
- Intraocular infection

**Conclusion**

Developments in intraocular oncology have been overwhelming in the past three decades with excellent responses to conservative treatment in both retinoblastoma and choroidal melanoma.

Solid tumors in retinoblastoma have shown good regression patterns with chemotherapy/focal thermal laser/localized brachytherapy. Subretinal tumor seeds show partial or complete response to therapy. Vitreous seeds are the least responsive and remain a major challenge. Management of small choroidal melanoma by observation or plaque radiation therapy remains controversial. Medium choroidal melanoma is better managed by brachytherapy as brachytherapy yields equivalent overall and melanoma metastasis-specific survival rates to enucleation for medium-sized melanomas. Large choroidal melanoma management still remains a challenge in terms of eye sparing techniques.

### References

1. Shields CL, Mashayekhi A, Au AK, *et al.* The International Classification of Retinoblastoma predicts chemoreduction success. *Ophthalmology*. 2006;113(12):2276–80.
2. The American Brachytherapy Society – Ophthalmic Oncology Task Force. The American Brachytherapy Society consensus guidelines for plaque brachytherapy of uveal melanoma and retinoblastoma. American Brachytherapy Society (2013).
3. Khetan V, Gopal L, Shanmugam MP, *et al.* Brachytherapy of intraocular tumors using 'BARC I-125 Ocu-Prosta seeds': an Indian experience. *Indian J Ophthalmol*. 2014;62(2):158–62.
4. Shields CL, Naseripour M, Cater J, *et al.* Plaque radiotherapy for large posterior uveal melanomas (0 or 58-mm thick) in 354 consecutive patients. *Ophthalmology*. 2002;109:1838–49.
5. Puusaari I, Heikkonen J, Kivelä T. Ocular complications after iodine brachytherapy for large uveal melanomas. *Ophthalmology*. 2004;111:1768–77.
6. Reese AB, Hyman GA, Merriam GR Jr, *et al.* Treatment of retinoblastoma by radiation and triethylenemelamine. *AMA Arch Ophthalmol*. 1954;53(4):505–13.
7. Kiribuchi M. Retrograde infusion of anti-cancer drugs to ophthalmic artery for intraocular malignant tumors [in Japanese]. *Nippon Ganka Gakkai Zasshi*. 1966;70:1829–33.
8. Yamane T, Kaneko A, Mohri M. The technique of ophthalmic arterial infusion therapy for patients with intraocular retinoblastoma. *Int J Clin Oncol*. 2004;9(2):69–73.
9. Suzuki S, Kaneko A. Management of intraocular retinoblastoma and ocular prognosis. *Int J Clin Oncol*. 2004;9(1):1–6.
10. Gobin P, Abramson D. A phase I/II study of intra-arterial (ophthalmic artery) chemotherapy for intraocular retinoblastoma [abstract 60]. *J Vasc Interv Radiol*. 2008;19(suppl 2):s24–5.
11. Yamane T, Kaneko A, Mohri M. The technique of ophthalmic arterial infusion therapy for patients with intraocular retinoblastoma. *Int J Clin Oncol*. 2004;9(2):69–73.
12. Shields Carol L., Manjandavida Fairouz P., Lally Sara E. Intra-arterial chemotherapy for retinoblastoma in 70 eyes outcomes based on the International Classification of Retinoblastoma. *Ophthalmology*. 2014;1–8.
13. Ericson LA, Kalberg B, Rosengren BH. Trials of intravitreal injections of chemotherapeutic agents in rabbits. *Acta Ophthalmol*. 1964;42(4):721–6.
14. Kaneko A, Suzuki S. Eye-preservation treatment of retinoblastoma with vitreous seeding. *Jpn J ClinOncol*. 2003;33(12):601–7.
15. Shields CL, Manjandavida FP, Arepalli S, *et al.* Intravitreal melphalan for persistent or recurrent retinoblastoma vitreous seeds: preliminary results. *JAMA Ophthalmol*. 2014;132(3):319–25.
16. Ghassemi F, Shields CL. Intravitreal melphalan for refractory or recurrent vitreous seeding from retinoblastoma. *Arch Ophthalmol*. 2012;130(10):1268–71.

**How to cite this article** Suganeswari G. Update on Intraocular Oncology, *Sci J Med & Vis Res Foun* 2015;XXXIII: 88–92.

# Retinopathy of Prematurity: An Update

Parveen Sen, Chetan Rao and Nishat Bansal

Sri Bhagwan Mahavir  
Vitreoretinal Services,  
Sankara Nethralaya

## Correspondence to:

Parveen Sen,  
Senior Consultant,  
Sri Bhagwan Mahavir  
Vitreoretinal Services,  
Sankara Nethralaya.  
E-mail: drpka@snmail.org

## Introduction

Retinopathy of prematurity (ROP) was originally designated as retrolental fibroplasias by Terry in 1952 who related it with premature birth.<sup>1</sup> Term ROP was coined by Heath in 1951.<sup>2</sup>

It is a disorder of development of retinal blood vessels in premature babies. Normal retinal vascularization happens centrifugally from optic disc to ora. Vascularization up to nasal ora is completed by 8 months (36 weeks) and temporal ora by 10 months (39–41 weeks).<sup>3</sup>

The incidence of ROP is increasing in India because of improved neonatal survival rate. Out of 26 million annual live births in India, approximately 2 million are <2000 g in weight and are at risk of developing ROP.<sup>3</sup> In India the incidence of ROP is between 38 and 51.9% in low-birth-weight infants.<sup>3,4</sup>

## Screening guidelines

American Academy of Pediatrics guidelines<sup>5</sup>

- Infants with birth weight of  $\leq 1500$  g.
- Gestational age of 30 weeks or less.
- Infants with birth weight between 1500 and 2000 g or gestational age of >30 weeks with unstable clinical course.

Indian scenario<sup>4</sup>

- Birth weight <1700 g
- Gestational age at birth <34–35 weeks
- Exposed to oxygen >30 days
- Infants born at <28 weeks and weighing <1200 g are particularly at high risk of developing severe form of ROP
- Presence of other factors such as respiratory distress syndrome, sepsis, multiple blood transfusions, multiple births (twins/triplets), apneic episodes, intraventricular hemorrhage increase risk of ROP. In these cases screening should be considered even for babies >37 weeks gestation or >1700 g birth weight.

The first screening should be done within 4 weeks (30 days) of life in infants with age >28 weeks of gestational age. Screening should be done earlier (2–3 weeks after birth) if gestational age is <28 weeks or birth weight is <1200 g.<sup>4</sup> Screening should be done by an ophthalmologist who is well versed with indirect ophthalmoscopy in ROP babies. Child should be fed 1 hour prior to examination. We use

1 ml of 10% phenylephrine (Drosyn) mixed in 3 ml of 1% tropicamide (after discarding 2 ml from 5 ml bottle) for pupillary dilatation. These combination drops are used every 15 minutes for 3 times. Punctum occlusion is mandatory after instilling the drops to reduce the systemic side effects of medication. Excess eye drops should also be wiped off to prevent absorption through cheek skin. If the pupil does not dilate in spite of proper use of medication, presence of plus disease should be suspected. Repeated installation of topical drops should be avoided to prevent systemic problems. Sterile Alfonso speculum is used to retract the lids and wire vectis for gentle depression.

High-quality retinal images obtained using commercially available wide-angle fundus camera like the Retcam followed by Telescreening by a trained ophthalmologist can also be done. In developing countries like India where majority of people live in remote areas which may not have access to the tertiary-level care, telescreening may bring more children into the screening program. This model has been successfully used by Vinekar et al. in Karnataka Internet Assisted Diagnosis of Retinopathy of Prematurity (KIDROP).<sup>6</sup> The follow up schedule for these babies is given in Table 1.

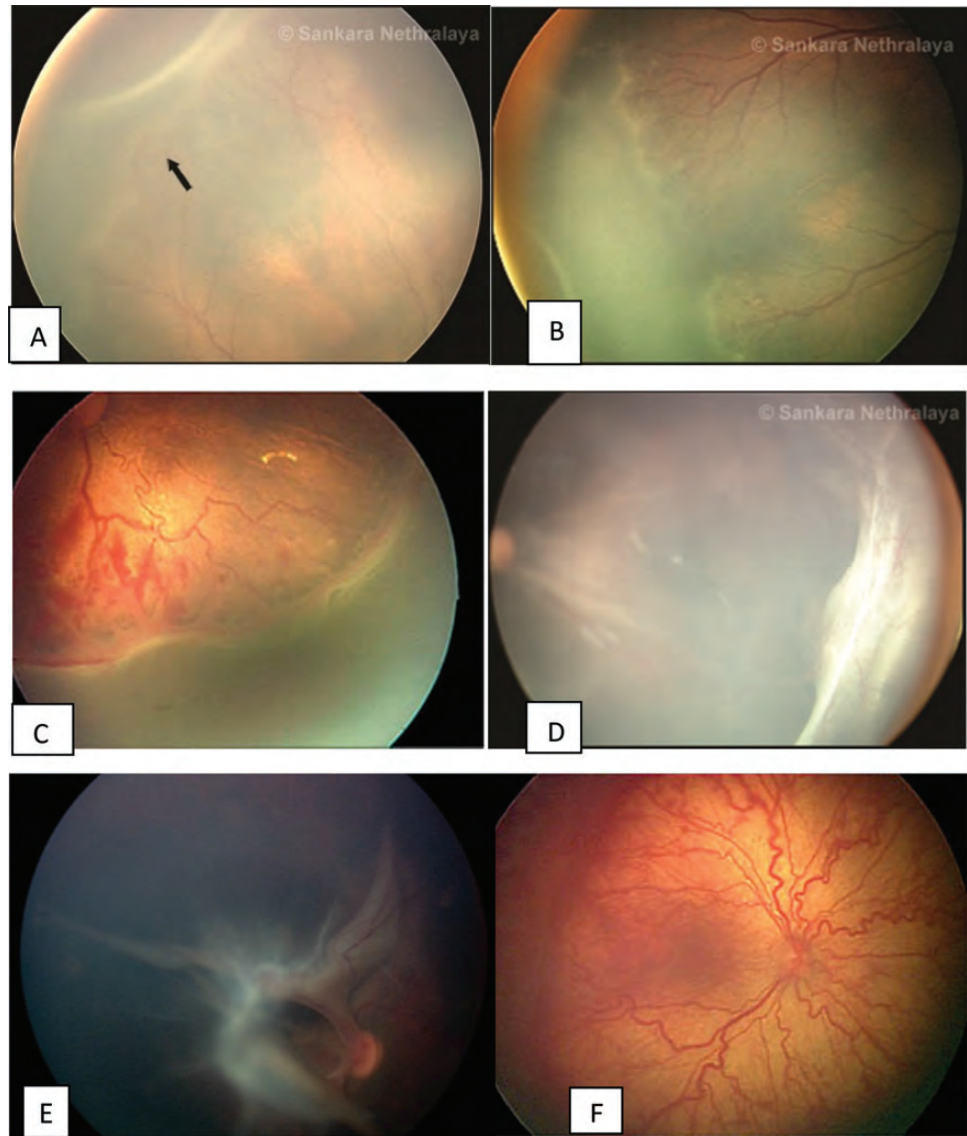
## Role of laser

Since the stimulus for abnormal vessels comes from the avascular retina therefore ablating the peripheral avascular retina is believed to cause regression of the ROP. Earlier the CRYO-ROP Study<sup>7</sup> treatment guidelines were followed; with the results of Early treatment for retinopathy of prematurity (ETROP study)<sup>8</sup> there has been a paradigm shift in treatment to laser therapy from CRYO therapy. Laser therapy significantly allows more precision of treatment as well as reduces the unfavorable side effects of the cryotherapy and has more than 90% successful results.<sup>8</sup> Laser treatment protocol according to ETROP is given in Table 2.

## Treatment guidelines

Laser is done using indirect laser ophthalmoscope under topical anesthesia after pupillary dilatation under care of an anesthetist in the operation theatre. The entire avascular retina up to the ora serrata should be ablated with near confluent burns (0.5–1 burn width apart) up to the ridge. Heart rate and apnea spells should be monitored throughout the laser.<sup>9</sup> In severe forms of disease not responding to this laser photocoagulation further laser to the ridge as well as posterior to





**Fig. 1** (A) Stage 1: Demarcation line. (B) Stage 2: Ridge. (C) Stage 3: Ridge with extra retinal fibrovascular proliferation. (D) Stage 4A: extrafoveal retinal detachment. (E) Stage 4B: fovea involving retinal detachment. (F) Plus disease with dilated and tortuous retinal vessels

**Table 1** Follow-up schedule for ROP babies<sup>4</sup>

Follow-up	Immature vascularization, no ROP	ROP Stage 1 or 2	ROP Stage 3	Regressing ROP
1 week or less	Zone I or immature retina extends into posterior zone II	Stage 1 or 2, zone I	Zone III, zone II pre-threshold	
1–2 weeks	Posterior zone II	Stage 2, zone II		Unequivocally regressing ROP, Zone I
2 weeks	Zone II	Stage 1, zone II		Unequivocally regressing ROP, Zone II
2–3 weeks		Stage 1 or 2, zone III		Regressing ROP, Zone III

ridge has also been shown to be effective in severe cases of ROP.<sup>10</sup> This has caused regression of the disease in some cases and avoided the progression of tractional retinal detachment.

Follow-up visits after laser treatment are usually weekly till the ROP regresses and involution of all tractional elements is seen and vascularization reaches the temporal ora.

**Table 2** Laser treatment protocol for ROP according to ETROP<sup>8</sup>

Zone 1		
No Plus	Stage 1	Follow
	Stage 2	Follow
	Stage 3	Treat
Plus	Stage 1	Treat
	Stage 2	Treat
	Stage 3	Treat
Zone 2		
No Plus	Stage 1	Follow
	Stage 2	Follow
	Stage 3	Follow
Plus	Stage 1	Follow
	Stage 2	Treat
	Stage 3	Treat

### Role of anti-vascular endothelial growth factor (VEGF)

In recent times, anti-VEGF has also been used in severe forms of ROP, especially those not responding to laser photocoagulation. Its role, however, is very controversial. VEGF is needed in premature babies for the normal organogenesis and vasculogenesis. Also systemic absorption may cause vascular development delay in other organs in these premature babies. Therefore, it is not recommended by many as the first-line therapy.<sup>5</sup>

BEAT ROP study which compared bevacizumab monotherapy with conventional laser therapy showed promising results for stage 3+ ROP in zone 1 but not in zone 2.<sup>11</sup> In this study, peripheral retinal vessels continued in normal fashion after treatment with intravitreal bevacizumab. This study was too small to assess the safety profile in these babies.<sup>11</sup>

The follow-up period after mono therapy is unpredictable as there can be a recurrence of neovascularization even beyond 54 weeks of post-gestational age. It is recommended that follow-up should be continued till there is no evidence of tractional elements and the vascularization reaches ora.<sup>5</sup> In Zone 1 ROP, the Laser treatment outcomes are poorer. Treatment with anti-VEGF followed by a 4–5 days later with laser treatment in these cases has improved the efficacy of laser along with a reduced need for extensive laser especially at the posterior pole.<sup>12</sup> In a study by Chen et al. both bevacizumab and ranibizumab had similar efficacy at the end of 1 year in terms of ROP regression and visual acuity.<sup>13</sup>

On the basis of available literature indication for anti-VEGF therapy can be enumerated as:

- 1 Primary therapy for aggressive posterior zone 1 disease (APROP).
- 2 Aggressive anterior ROP or media haze due to aggressive posterior disease to improve visualization for laser treatment.

- 3 Failed laser treatment leading to persistent neovascularization, tractional elements or tractional retinal detachment prior to surgery.

### Role of surgery

Surgery is done for tractional retinal detachment (TRD) repair as seen in Stages 4 and 5 ROP. The aim for surgical intervention in Stage 4 ROP is to prevent progression of retinal detachment. Scleral buckling (placing 240 band at the height of the TRD by making sclera tunnels in all quadrants) is done for Stage 4A ROP with only peripheral tractional retinal detachment. This surgery does not involve the removal of membranes formed on the retina but by causing peripheral scleral indentation reduces the effective TRD. This procedure can be combined with cryotherapy or laser to any peripheral persistent new vessels. The encircling band needs to be removed once the child is 1 year of age to allow normal growth of the eyeball and to reduce the amount of anisometropia induced by the buckle.

Lens sparing vitrectomy (LSV) has shown promising results in Stages 4A and 4B. Long-term results with lens sparing vitrectomy were favorable in the study by Trese et al.: 82.1% (Stage 4A), 69.5% (Stage 4B) and 42.6% (Stage 5) showing successful anatomical reattachment of retina with lens being clear for at least the first decade of life.<sup>14</sup> Bhende et al. also reported 82% anatomical success in 4A stage ROP and 50% in Stage 4B ROP after single procedure.<sup>15</sup> 25-Gauge vitrectomy is now commonly used for ROP surgery. Finer instrumentation and more effective microvitre systems in small gauges are useful during membrane dissection. However, modification of the technique in the form of conjunctival dissection as well as suturing of the sclerotomies at the end of surgery may be necessary.<sup>16</sup> Modern vitreoretinal surgical tools like the infusion light pipe, binocular indirect ophthalmoscopy (BIOM) which allows wide-angle viewing has reduced the risk of creating iatrogenic retinal breaks and also sparing of lens, allowing easy visual rehabilitation in these children.<sup>17</sup>

In Stage 5 ROP, the results of surgical intervention are poor. It usually involves the removal of the lens. Gopal et al. had anatomical success with the attachment of posterior pole in 22.5% of cases with lens sacrificing vitrectomy though visual results were unsatisfactory with only two children showing mobile vision out of 96 eyes.<sup>18</sup> Closed globe vitreoretinal surgery was done in all these eyes with Stage 5 ROP. The aim of the surgery for Stage 5 ROP is to clear all preretinal tissue up to the disc and open the peripheral trough all round. In most instances, bimanual surgery under viscoelastic is performed. Anterior chamber (AC) maintainer to keep the IOP under control during surgery is also used. Fixation of infusion cannula

through pars plicata is impossible in these cases because the retina is pulled up to the lens.

Open sky vitrectomy (through a trephined corneal opening) has also been advocated by some especially in cases with corneal opacity.<sup>19</sup> It has the advantage of allowing two hand dissection from a large anterior incision but maintenance of intraocular pressure is difficult.

### Conclusion

Considering the poor outcome of surgery in end-stage ROP timely intervention in the form of laser treatment is the best treatment option. There is need to increase the awareness of the disease to make sure these babies can be treated on time. Also there is a need of more numbers of specialized vitreoretinal surgeons who can handle these babies.

### References

1. Terry TL. Extreme prematurity and fibroblastic overgrowth of persistent vascular sheath behind each crystalline lens. I. Preliminary report. *Am J Ophthalmol.* 1942;25:203-4
2. Heath P. Pathology of retinopathy of prematurity, RLF. *Am J Ophthalmol.* 1951;34:1249-68.
3. Pejavar R, Vinekar A, Bilagi A. *National Neonatology Foundation's Evidence-based Clinical Practise Guidelines (2010), Retinopathy of Prematurity*, NNF India, New Delhi 2010:253-62.
4. Jalali S, Anand R, Kumar H, Dogra MR, Azad R, Gopal L. Programme planning and screening strategy in retinopathy of prematurity. *Indian J Ophthalmol.* 2003;51(1):89-99.
5. Fierson WM. Screening examination of premature infants for retinopathy of prematurity. *Pediatrics.* 2013;131:189-95.
6. Vinekar A, Gilbert C, Dogra M, Kurian M, Shainesh G, Shetty B, Bauer N. The KIDROP model of combining strategies for providing retinopathy of prematurity screening in underserved areas in India using wide-field imaging, tele-medicine, non-physician graders and smart phone reporting. *Indian J Ophthalmol.* 2014;62(1):41-9.
7. Cryotherapy for retinopathy of prematurity cooperative group. Multicentric trial of retinopathy of prematurity: 3 months outcome. *Arch Ophthalmol.* 1990;108:195-204.
8. Early Treatment of Retinopathy of Prematurity Cooperative Group. Revised indications for treatment of retinopathy of prematurity: results of early treatment of retinopathy of prematurity randomized trial. *Arch Ophthalmol.* 2003;121:1684-96.
9. Jalali S, Azad R, Trehan HS, Dogra MR, Gopal L, Narendran V. Technical aspects of laser treatment for acute retinopathy of prematurity under topical anesthesia. *Indian J Ophthalmol.* 2010;58(6):509-15.
10. Uparkar M, Sen P, Rawal A, Agarwal S, Khan B, Gopal L. Laser photocoagulation (810 nm diode) for threshold retinopathy of prematurity: a prospective randomized pilot study of treatment to ridge and avascular retina versus avascular retina alone. *Int Ophthalmol.* 2011;31(1):3-8.
11. Mintz-Hittner HA, Kennedy KA, Chuang AZ; BEAT-ROP Cooperative Group. Efficacy of intravitreal bevacizumab for stage 3+ retinopathy of prematurity. *N Engl J Med.* 2011;364(7):603-15.
12. Mota A, Carneiro A, Breda J, Rosas V, Magalhaes A, Silva R, Falcao-Reis F. Combination of intravitreal ranibizumab and laser photocoagulation for aggressive posterior retinopathy of prematurity. *Case Rep Ophthalmol.* 2012;3(1):136-41.
13. Chen SN, Lian I, Hwang YC, Chen YH, Chang YC, Lee KH, Chuang CC, Wu WC. Intravitreal anti-vascular endothelial growth factor treatment for retinopathy of prematurity: comparison between ranibizumab and bevacizumab. *Retina.* 2015;35(4):667-74.
14. Nudleman E, Robinson J, Rao P, Drenser KA, Capone A, Trese MT. Long-term outcomes on lens clarity after lens-sparing vitrectomy for retinopathy of prematurity. *Ophthalmology.* 2015;122(4):755-9.
15. Bhende P, Gopal L, Sharma T, Verma A, Biswas RK. Functional and anatomical outcomes after primary lens-sparing pars plana vitrectomy for Stage 4 retinopathy of prematurity. *Indian J Ophthalmol.* 2009;57(4):267-71.
16. Gonzales CR, Boshra J, Schwartz SD. 25-Gauge pars plicata vitrectomy for stage 4 and 5 retinopathy of prematurity. *Retina.* 2006;26(7 Suppl):S42-6.
17. Trese MT, Capone A Jr. Surgical approach to infant and childhood retinal diseases: invasive methods. In Hartnett ME, Tresse MT, Capone A Jr, et al, eds. *Pediatric Retina*. Philadelphia: Lipponcott Williams& Williams; 2005, pp. 359-64.
18. Gopal L, Sharma T, Shanmugam M, Badrinath SS, Sharma A, Agraharam SG, Choudhary A. Surgery for stage 5 retinopathy of prematurity: the learning curve and evolving technique. *Indian J Ophthalmol.* 2000;48(2):101-6.
19. Tasman W, Borrone RN, Bolling J. Open sky vitrectomy for total retinal detachment in retinopathy of prematurity. *Ophthalmology.* 1987;94(4):449-52.

**How to cite this article** Parveen S, Chetan R, Nishant B. Retinopathy of Prematurity: An Update, *Sci J Med & Vis Res Foun* 2015;XXXIII:93-96.

# Current Role of Photodynamic Therapy in Ophthalmic Practice

Pukhraj Rishi and Vishvesh Agarwal

Shri Bhagwan Mahavir  
Vitreoretinal Services,  
Sankara Nethralaya,  
18 College Road,  
Chennai 600006,  
India

**Correspondence to:**  
Pukhraj Rishi,  
Senior Consultant,  
Shri Bhagwan Mahavir  
Vitreoretinal Services,  
Sankara Nethralaya.  
E-mail: docrishi@yahoo.co.in

## Introduction

Photodynamic therapy (PDT) is a form of light-therapy using light-sensitive compounds that when exposed to light selectively become toxic to targeted cells (phototoxicity).<sup>1</sup> Most PDT applications involve three components: a photosensitizer, a light source and tissue oxygen. The combination of these three components leads to chemical destruction of tissues which have taken-up the photosensitizer and have been locally exposed to light of appropriate wavelength to produce reactive oxygen species (ROS). These ROS are free radicals (Type I PDT) generated through electron abstraction or transfer from a substrate molecule and highly reactive state of oxygen known as singlet oxygen (Type II PDT). It is important to distinguish PDT from other light-based and laser therapies such as laser wound healing and rejuvenation, or intense pulsed light hair removal, which do not require a photosensitizer. PDT is used clinically to treat a wide range of medical conditions.<sup>2</sup> The era of PDT in Ophthalmology was initiated by results of the TAP study.<sup>3</sup> The first indication for which PDT was approved in ophthalmology was choroidal neovascularization (CNV) in patients with age-related macular degeneration (AMD).

The technique of administering PDT requires the combination of laser and photosensitizer Visudyne®. PDT utilizes photosensitizer Visudyne® [liposomal benzoporphyrin derivative monoacid ring A (BPDMA)] given via intravenous infusion at a dose of 6 mg/m<sup>2</sup> of body surface area. Fifteen minutes after the infusion, the 'standard' protocol of focal light (light dose of 50 J/cm<sup>2</sup>, irradiance of 600 mW/cm<sup>2</sup> of 689 nm light over 83 seconds) is delivered. This treatment is 'selective' in that the photosensitizer is selectively taken up by the proliferating endothelial cells of the neovascular tissue thus leading to occlusion and reducing collateral damage. PDT was first recommended for cases of subfoveal classic or occult CNV in AMD.<sup>5</sup>

The approval of intravitreal Ranibizumab for treatment of CNV in AMD has led to decline in the use of PDT. The main advantage of anti-VEGF when compared with PDT is more improvement in BCVA (77% vs 28%) and less reduction in BCVA (21% vs 60%) at 2-year follow-up.<sup>6</sup> PDT is currently recommended for CNV in AMD either refractory to anti-VEGF therapy or as monotherapy in patients with contraindications for anti-VEGF therapy.<sup>7</sup>

The PDT use in myopic CNV was established by the results of the VIP reports 1 and 2 where reduction in BCVA was less with PDT as compared to placebo (36% patients lost at least eight EDTRS letters as compared to 51% with placebo) while more number of patients had improvement in BCVA (improvement in BCVA of at least five EDTRS letters was seen in 40% with PDT as compared to 13% with placebo) at 24-month follow-up.<sup>8,9</sup> Currently, PDT is recommended for use in myopic CNV in cases where anti-VEGF has been ineffective or is contraindicated.<sup>10</sup>

In patients with CNV due to angioid streaks, stability in BCVA is achieved with the use of PDT.<sup>11</sup> However, the success rate achieved with anti-VEGF in angioid streaks by Browning et al. tilted the balance towards anti-VEGF as the preferred modality of treatment.<sup>12</sup> PDT has also been used with some success in cases of inflammatory CNV due to multifocal choroiditis, punctate inner choroidopathy (PIC) and toxoplasmosis.<sup>13</sup>

Polypoidal choroidal vasculopathy (PCV) is a disorder characterized by subretinal polypoidal vascular lesions. PDT was found to be successful in improving BCVA in 56% cases and maintaining vision in 31% cases of PCV.<sup>14</sup> Currently, PDT is recommended for treatment of juxtafoveal and subfoveal PCV, alone or in combination with intravitreal Ranibizumab (0.5 mg/0.1 ml).<sup>15</sup>

Central serous chorioretinopathy (CSCR) is a disorder characterized by pigmentary epithelial detachment with subretinal fluid. The use of PDT is based on the rationale that primary choroidal hyperpermeability is the basic cause of CSCR. Treatment with PDT leads to visual improvement of  $\geq 2$  lines in 43% cases while loss of  $\geq 2$  lines of BCVA occurs in about 7.5% cases. RPE atrophy seen in about 4% cases.<sup>16</sup>

Apart from retinal lesions, various ocular tumors have been treated with PDT with variable success rates. PDT is the one of the treatment alternatives in recurrent choroidal melanoma.<sup>17</sup> PDT is also a good option for treatment of symptomatic choroidal nevi, especially in cases with subretinal fluid. However, despite resolution of subretinal fluid, it does not provide good local tumor control.<sup>18,19</sup>

The use of PDT in patients with retinal capillary hemangioblastomas achieves regression of the tumor, resolution of macular edema. However, improvement in BCVA is not always seen (around 50% cases).<sup>20,21</sup> On the contrary, the use of PDT

in choroidal hemangioma achieves excellent tumor control, resolution of macular edema as well as exudative macular detachment along with improvement in BCVA. This has made PDT as the preferred treatment option for cases of choroidal hemangioma.<sup>22,23</sup> There are a number of other ocular tumors such as vasoproliferative tumors of the retina, choroidal osteoma, retinal astrocytoma where PDT has been used with variable success rates.<sup>24–26</sup>

Ocular surface squamous neoplasia (OSSN) is an ocular condition characterized by growth of neovascular tissue on the surface of the cornea and sclera. PDT was first used for treatment of OSSN by Barbazetto *et al.* This led to its use for treating OSSN, without extensive invasion, which is its current indication.<sup>27,28</sup>

With the growing evidence in support of PDT for successful treatment of various retinal neovascular lesions, the use of PDT in corneal neovascularization for prevention of corneal graft rejection was explored. PDT achieves an immediate reduction in corneal neovascularization with decreased neovascularization maintained in 75% and complete vascular occlusion achieved in 50% of treated eyes at 1-year follow-up. Recently, PDT has also been used in combination with subconjunctival Bevacizumab for the treatment of corneal neovascularization. A triple combination of PDT, subconjunctival Bevacizumab and topical cyclosporine has also been tried.<sup>29–31</sup>

However, with the growing utility of PDT in ocular conditions, its side-effects warrant consideration, too. The most common systemic side-effects encountered are infusion-related back pain and minor allergic reactions at the injection site. Cases of serious allergic reactions are extremely rare though. Sunlight exposure is to be avoided for 3 days following PDT to avoid sunburn. The most important ocular side effects are secondary CNV, persistent choriocapillaris hyperperfusion and pigmentary changes in the RPE in the treated area.<sup>32</sup> All these concerns have led to the exploration of reduced fluence PDT (irradiance of 300 mW/cm<sup>2</sup> instead of 600 mW/cm<sup>2</sup>) by some authors with success rates similar to those achieved with standard fluence. A novel approach has been reducing the dose of verteporfin from 6 to 3 mg/m<sup>2</sup>. This modification has achieved success rates similar to the standard fluence PDT but with the theoretical advantage of reduced scarring.<sup>33–35</sup>

In conclusion, indications of PDT extend from ocular surface conditions to intraocular tumors, making it a useful tool in the armamentarium of the ophthalmologist.

## References

1. Moan J, Peng Q. An outline of the hundred-year history of PDT. *Anticancer Res.* 2003; 23(5A):3591–600.

2. Diamond I, Granelli SG, McDonagh AF, Nielsen S, Wilson CB, Jaenicke R. Photodynamic therapy of malignant tumours. *Lancet.* 1972;2:1175–7.
3. Treatment of age-related macular degeneration with photodynamic therapy (TAP) study group. Photodynamic therapy of subfoveal choroidal neovascularization in age-related macular degeneration with Verteporfin. *Arch Ophthalmol.* 1999;117:1329–45.
4. van den Bergh H. Photodynamic therapy of age-related macular degeneration: history and principles. *Sem Ophthalmol.* 2001;16:181–200.
5. Verteporfin in Photodynamic Therapy Study Group. Verteporfin therapy of subfoveal choroidal neovascularization in age-related macular degeneration: two-year results of a randomized clinical trial including lesions with occult with no classic choroidal neovascularization—verteporfin in photodynamic therapy report 2. *Am J Ophthalmol.* 2001;131:541–60.
6. Brown DM, Michels M, Kaiser PK, Heier JS, Sy JP, Ianchulev T; ANCHOR Study Group. Ranibizumab versus verteporfin photodynamic therapy for neovascular age-related macular degeneration: two-year results of the ANCHOR study. *Ophthalmology.* 2009;116(5):57–65.
7. Schmidt-Erfurth U, Chong V, Loewenstein A, Larsen M, Souied E, Schlingemann R, Eldem B, Monés J, Richard G, Bandello F. Guidelines for the management of neovascular age-related macular degeneration by the European Society of Retina Specialists (EURETINA). *Br J Ophthalmol.* 2014;98:1144–67.
8. Verteporfin in Photodynamic Therapy (VIP) Study Group. Photodynamic therapy of subfoveal choroidal neovascularization in pathologic myopia with verteporfin: 1-year results of a randomized clinical trial—VIP report 1. *Ophthalmology.* 2001;108:841–52.
9. Blinder KJ, Blumenkranz MS, Bressler NM, Bressler SB, Donato G, Lewis H, Lim JI, Menchini U, Miller JW, Mones JM, Potter MJ, Pourmaras C, Reaves A, Rosenfeld P, Schachat AP, Schmidt-Erfurth U, Sickenberg M, Singerman LJ, Slakter JS, Strong HA, Virgili G, Williams GA. Verteporfin therapy of subfoveal choroidal neovascularization in pathologic myopia: 2-year results of a randomized clinical trial—VIP report no. 3. *Ophthalmology.* 2003;110:667–73.
10. Wong TY, Ohno-Matsui K, Levezuel N, Holz FG, Lai TY, Yu HG, Lanzetta P, Chen Y, Tufail A. Myopic choroidal neovascularisation: current concepts and update on clinical management. *Br J Ophthalmol.* 2014;1–8.
11. Browning AC1, Chung AK, Ghanchi F, Harding SP, Musadiq M, Talks SJ, Yang YC, Amoaku WM; United Kingdom PDT Users Group. Verteporfin photodynamic therapy of choroidal neovascularization in angioid streaks: one-year results of a prospective case series. *Ophthalmology.* 2005;112:1227–31.
12. Neri P, Salvolini S, Mariotti C, Mercanti L, Celani S, Giovannini A. Long-term control of choroidal neovascularisation secondary to angioid streaks treated with intravitreal bevacizumab (Avastin). *Br J Ophthalmol.* 2009;93:155–8.
13. Ruiz-Moreno JM, Montero JA, Arias L, Sanabria MR, Coco R, Silva R, Araiz J, Gomez-Ulla F, Garcia-Layana A. Photodynamic therapy in subfoveal and juxtafoveal idiopathic and postinflammatory choroidal neovascularization. *Acta Ophthalmol Scand.* 2006;84(6):743–48.
14. Spaide RF1, Donsoff I, Lam DL, Yannuzzi LA, Jampol LM, Slakter J, Sorenson J, Freund KB. Treatment of polypoidal choroidal vasculopathy with photodynamic therapy. *Retina.* 2002;22:529–35.
15. Koh A1, Lee WK, Chen LJ, Chen SJ, Hashad Y, Kim H, Lai TY, Pilz S, Ruamviboonsuk P, Tokaji E, Weisberger A, Lim TH. EVEREST study: efficacy and safety of verteporfin photodynamic therapy in combination with ranibizumab or

- alone versus ranibizumab monotherapy in patients with symptomatic macular polypoidal choroidal vasculopathy. *Retina*. 2012;32:1453–64.
16. Lim JJ, Glassman AR, Aiello LP, Chakravarthy U, Flaxel CJ, Spaide RF. Macula Society CSC Collaborative Study Group, Research and Education Committee and Website Committee. Collaborative retrospective macula society study of photodynamic therapy for chronic central serous chorioretinopathy. *Ophthalmology*. 2014;121(5):1073–8.
  17. Canal-Fontcuberta I, Salomão DR, Robertson D, Cantrill HL, Koozekanani D, Rath PP, *et al* Clinical and histopathologic findings after photodynamic therapy of choroidal melanoma. *Retina*. 2012;32:942–948.
  18. García-Arumí J, Amselem L, Gunduz K, Badal J, Adan A, Zapata MA, Valleperas X, Huste F, Corcóstegui B. Photodynamic therapy for symptomatic subretinal fluid related to choroidal nevus. *Retina*. 2012;32(5):936–41.
  19. Rundle P, Rennie I. Management of symptomatic choroidal naevi with photodynamic therapy. *Eye (Lond)*. 2007;21:1531–1533.
  20. Papastefanou VP, Pilli S, Stinghe A, Lotery AJ, Cohen VML. Photodynamic therapy for retinal capillary hemangioma. *Eye (Lond)*. 2013;27:438–442.
  21. Sachdeva R, Dadgostar H, Kaiser PK, Sears JE, Singh AD. Verteporfin photodynamic therapy of six eyes with retinal capillary hemangioma. *Acta Ophthalmol*. 2010;88(8):334–40.
  22. Singh AD, Kaiser PK, Sears JE, Gupta M, Rundle PA, Rennie IG. Photodynamic therapy of circumscribed choroidal haemangioma. *Br J Ophthalmol*. 2004;88:1414–18.
  23. Porrini G, Giovannini A, Amato G, Ioni A, Pantanetti M. Photodynamic therapy of circumscribed choroidal hemangioma. *Ophthalmology*. 2003;110(4):674–80.
  24. Eskelin S, Tommila P, Palosaari T, Kivelä T. Photodynamic therapy with verteporfin to induce regression of aggressive retinal astrocytomas. *Acta Ophthalmol*. 2008;86(7):794–9.
  25. Shields CL, Materin MA, Mehta S, Foxman BT, Shields JA. Regression of extrafoveal choroidal osteoma following photodynamic therapy. *Acta Ophthalmologica* . 2008;1:135–137.
  26. Blasi MA, Scupola A, Tiberti AC, Sasso P, Balestrazzi E. Photodynamic therapy for vasoproliferative retinal tumors. *Retina*. 2006;26:404–9.
  27. Cekic O, Bardak Y, Kapucuoglu N. Photodynamic therapy for conjunctival ocular surface squamous neoplasia. *J Ocular Pharmacol Therapeutics*. 2011;27(2):205–7.
  28. Barbazetto IA, Lee TC, Abramson DH. Treatment of conjunctival squamous cell carcinoma with photodynamic therapy. *Am J Ophthalmol*. 2004;138:183–9.
  29. You IC, Im SK, Lee SH, Yoon KC. Photodynamic therapy with verteporfin combined with subconjunctival injection of bevacizumab for corneal neovascularization. *Cornea*. 2011;30(1):30–3.
  30. Yoon KC, You IC, Kang IS, Im SK, Ahn JK, Park YG, Ahn KY. Photodynamic therapy with verteporfin for corneal neovascularization. *Am J Ophthalmol*. 2007;144(3):390–5.
  31. Kirat O, Al-Dhibi HA. Regression of aggressive corneal vascularization after photodynamic therapy, subconjunctival Avastin injections and topical cyclosporin-A 1% drops: a case report. *Saudi J Ophthalmol*. 2010; 24:151–4.
  32. Wormald R, Evans JR, Smeeth LL, Henshaw KS. Photodynamic therapy for neovascular age-related macular degeneration. Analysis 1.13. Comparison 1 photodynamic therapy with verteporfin versus placebo, outcome. *Cochrane Rev*. 2009;4:45–46.
  33. Reibaldi M, Cardascia N, Longo A, Furino C, Avitabile T, Faro S, Sanfilippo M, Russo A, Uva MG, Munno F, Cannemi V, Zagari M, Boscia F. Standard-fluence versus low-fluence photodynamic therapy in chronic central serous chorioretinopathy: a nonrandomized clinical trial. *Am J Ophthalmol*. 2010;149(2):307–15.
  34. Lai TY, Chan WM, Li H, Lai RY, Liu DT, Lam DS. Safety enhanced photodynamic therapy with half dose verteporfin for chronic central serous chorioretinopathy: a short term pilot study. *Br J Ophthalmol*. 2006;90:869–74.
  35. Koytak A, Erol K, Coskun E, Asik N, Öztürk H, Öztürk Y. Fluorescein angiography-guided photodynamic therapy with half-dose verteporfin for chronic central serous chorioretinopathy. *Retina*. 2010;30(10):1698–703.

**How to cite this article** Rishi P, Agarwal V. Current Role of Photodynamic Therapy in Ophthalmic Practice, *Sci J Med & Vis Res Foun* 2015;XXXIII:97–99.

# Techniques of Fundus Imaging

Amit B. Jain, Vadivelu Jaya Prakash and Muna Bhende

Shri Bhagwan Mahavir  
Vitreoretinal Services,  
Sankara Nethralaya

**Correspondence to:**  
Vadivelu Jaya Prakash  
Associate Consultant,  
Shri Bhagwan Mahavir  
Vitreoretinal Services,  
Sankara Nethralaya  
Email: drvjp@snmail.org

## Introduction

Ophthalmology is a specialized field of medicine, where we can directly visualize the pathology and treat accordingly. Imaging of fundus helps in documenting the disease process which further helps in classifying, treating and following up effectively. Fundus imaging helps in diagnosing various ocular and systemic disorders like diabetic retinopathy, hypertensive retinopathy, age-related macular degeneration, glaucoma, subacute bacterial endocarditis, leukemia, systemic malignancy with ocular metastasis etc. and thus helps in effectively managing the condition. This review focuses on various fundus imaging modalities such as digital fundus photography, autofluorescence, infrared reflectance, etc. making a note of recent advances in fundus imaging technology. The history of fundus imaging dates back to early 20th century, but it has advanced as time has progressed. With the advent of digital imaging, the film-based imaging is almost an obsolete technique now. Table 1 summarizes the major differences in film-based and digital imaging.

Fundus imaging can be defined as a two-dimensional image of a three-dimensional retinal tissue captured using reflected light. Fundus imaging can be categorized into contrast and non-contrast modalities as shown in Table 2.

Discussion in this review will be limited to non-contrast techniques of fundus imaging along with recent advances. A detailed discussion on FFA and ICG is beyond the scope of this review. The list of available machines mentioned is by no means exhaustive and does not indicate any commercial interest of the authors.

## Red free fundus photography

It is a technique of monochromatic retinal imaging which uses green contrast filters to modify individual tones in monochrome images and the increased scattering of light at shorter wavelengths. Various fundus structures can be better visualized by limiting the spectral range of the illuminating source.<sup>3</sup>

Green light enables excellent contrast and view of fundus as the peak spectral sensitivity of the human eye falls in the green-yellow portion of the spectrum. Less scatter compared to shorter wavelengths, results in a better view even in media opacities. Retinal vasculature and nerve fiber layer (RNFL) are best seen in red free photography, thus helping in better identification of hemorrhages, drusen, microaneurysms, RNFL defects and exudates. For this reason, green filter 'red-free' photos are routinely taken as baseline images before fluorescein angiography.<sup>4</sup>

**Table 1** Comparison of digital fundus and film-based fundus imaging<sup>1</sup>

	Digital	Film-based
Resolution	1000 pixels	10000 pixels (in ideal conditions)
Stereoscopic viewing	Available	Available
Image manipulation	Easy	Difficult
Processing and duplication time	Seconds	Hours
Lesion measurement	Irregular tracing made easy	Best fit circles
Transmission	Worldwide via internet (instantaneous)	Manual delivery of copies (slow)
Cost	Installation cost high	Installation cost less

**Table 2** Various imaging modalities based on use of contrast

Contrast	Non-contrast
Fluorescein angiography (FFA)	1. Red-free photography
Indocyanine angiography (ICG)	2. Color fundus photography
	a Stereo fundus photography
	b Digital fundus photography
	c Confocal scanning laser ophthalmoscopy (cSLO)
	3. Fundus autofluorescence
	4. Infrared reflectance
	5. Hyperspectral retinal imaging
	6. Adaptive optics SLO

## Color fundus imaging


### A. Stereo-imaging

Diagnostic information can be greatly improved by creating a visual sense of depth by laterally shifting the fundus camera a few millimeters between sequential photographs. The illuminating beam of the fundus camera falls on opposite slopes of the cornea creating a cornea-induced parallax.<sup>4</sup> This results in pseudo three-dimensional image formation from an ordinary two-dimensional fundus photographs. Dedicated stereo display software is available for accurate alignment of digital stereo images.<sup>4</sup>

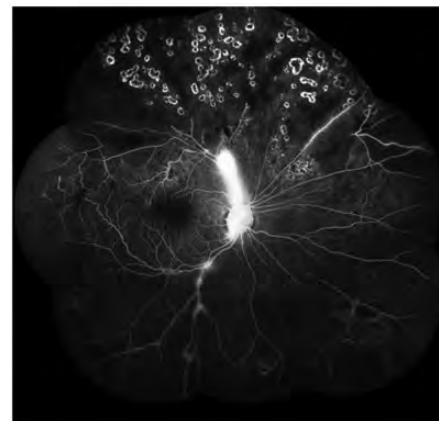
### B. Digital fundus photography

Carl Zeiss Company in 1926 introduced the first commercially available fundus camera which provided a 20° field of view of the retina.<sup>5</sup> Traditionally used fundus cameras (Fig. 1) provide 30° to 45° field of view which can subsequently be increased by mosaic or montage patterns.

Imaging beyond 50° is called wide-field photography and the recent development came with the introduction of 'ultrawidefield' photography. These include the Pomerantzeff camera,<sup>6</sup> the Retcam (Clarity Medical Systems, Inc., Pleasanton, CA, USA), the Panoret-1000™ camera (Medibell Medical Vision Technologies, Haifa, Israel), the Optos® camera (Optos PLC, Dunfermline, UK), and the Staurenghi lens<sup>7</sup> (Ocular Staurenghi 230 SLO Retina Lens; Ocular Instruments Inc, Bellevue, WA, USA) etc. allowing 100° to 200° view of fundus. This allows for simultaneous evaluation of the peripheral and central retina without causing any patient discomfort.



**Figure 1.** Zeiss FF 450 plus IR colour fundus camera which provides good quality colour fundus images with optical zoom of three magnification levels (20°, 30° and 50°) and FFA along with the option of adding ICG and FAF to its software.



**Figure 2.** Montage of FFA of the right eye of a patient with vasculitis showing neovascularisation at the disc along with extensive capillary nonperfusion areas and laser marks superiorly. Note the enlarged view obtained by montage technique (approximately 75°).

### C. Confocal scanning laser ophthalmoscopy imaging

Some of the newer imaging techniques use the principle of confocal scanning laser ophthalmoscopy (cSLO). Instead of a bright flash of white light as in traditional photography, cSLO uses laser light to illuminate the retina. Confocal imaging acts by a detailed point-by-point scanning of the entire field by a focused laser beam and then capturing the reflected light through a small confocal pinhole, which in turn suppresses any scattered or reflected light outside the focal plane that could blur the image. This result in a sharp, high-contrast image of an object layer located within the focal plane.<sup>8,9</sup>

The advantages of using cSLO over traditional fundus photography include improved image quality, suppression of scattered light, and patient comfort through less bright light, three-dimensional imaging capability, video capability, and effective imaging of patients who do not dilate well. Examples of cSLO-based ultrawidefield imaging (UWFI) systems include the Optos® camera (Optos PLC, Dunfermline, UK), and Spectralis® (Heidelberg Retina Angiograph (HRA 2), Heidelberg Engineering, Germany).

The main limitation in wide-field imaging is the difficulty in projecting a curved surface on a flat two-dimensional plane (Greenland effect) and software are being developed to address this. Research is also going on to determine whether retinal surface area can be precisely measured in square millimeters.<sup>10</sup>

### Fundus autofluorescence

Fluorescein angiography uses fluorescein dye to delineate retinal vascular and associated



pathology, the basic nature of dye to cause fluorescence helps in the diagnostic ability. The human eye itself has few components which fluoresce without any external addition of dye. Imaging of such auto-fluorescing substances has given an altogether new dimension to diagnostic imaging. Fundus autofluorescence imaging takes advantage of the intrinsic autofluorescence of lipofuscin, normally found in RPE cells accumulated as a result of phagocytosis of the constantly shed photoreceptor outer segments. RPE dysfunction leads to an imbalance between lipofuscin formation and clearance resulting in excessive accumulation of lipofuscin.<sup>11</sup> Higher the lipofuscin content of the RPE cell, the more autofluorescent it will appear on FAF. Atrophic (dead) RPE cells appear severely hypoautofluorescent as they do not contain lipofuscin, whereas viable cells have a varying content of lipofuscin and accordingly, a varying degree of hyperautofluorescence.

Modified fundus cameras use a single flash with excitation spectrum of 535–585 nm to record a single image whereas confocal-based systems use continuous scanning with an excitation spectrum of 488 nm resulting in recording of multiple images with averaging to obtain a final image of high resolution. Overall image quality and contrast are maximized with the cSLO's multiple image acquisition and mean image calculation.<sup>12</sup>

FAF imaging gives information about the metabolic changes at the level of the RPE and helps to identify areas that may be at high risk for the development of geographic atrophy or CNV. FAF imaging has helped us with better understanding of various diseases, classification, prognostication, and follow up in conditions like ARMD, CSR, Stargardt's disease, Leber's congenital amaurosis and Serpiginous choroiditis.<sup>11,13–17</sup>

### Infrared reflectance

A newer variant of fundus photography, infrared reflectance (IR) imaging uses infrared light instead of white light for illumination. Red wavelengths

are longer than the other colored wavelengths of the visible spectrum making them less prone to absorption by blood and melanin. This results in greater amount of light (reflectance) being available to form an image as compared to shorter wavelengths in the visible spectrum, and hence constitute better tool for imaging structures deeper to the RPE.<sup>18,19</sup>

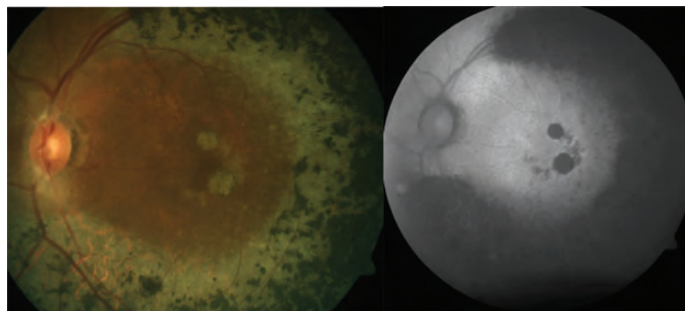
IR is a non-invasive en face imaging technique which helps in visualizing sub-retinal pathology.<sup>18</sup> IR imaging has several advantages over flash fundus photography. The invisibility of infrared light makes it better acceptable for imaging children and light-sensitive patients. As the penetration of infrared light is better, it acts as a useful imaging tool in patient with media opacities like dense cataract. IR imaging may offer better visualization of epiretinal membranes, cystoid macular edema and deeper structures compared to fundus photography and red-free imaging. IR was found to be superior to standard color fundus photography in screening for neovascular AMD.<sup>19</sup>

### Hyperspectral retinal imaging

It is a novel, non-invasive imaging technique for ocular diagnosis using the spectroscopy principle of retinal oximetry, which exploits the different spectral characteristics of oxygenated vs deoxygenated hemoglobin to assess tissue perfusion. This enables evaluation of functional characteristics of tissue health. Its role is important in microvascular disorders like diabetic retinopathy, sickle cell disease, ARMD.<sup>20,21</sup>

### Adaptive optics SLO

The optical properties of the normal eye result in a point spread function width approximately the size of a photoreceptor. Standard fundus cameras have the shortcomings of inability to visualize individual cells/structure because of the various aberrations of the visual system. Adaptive optics uses mechanically activated mirrors to correct the wavefront aberrations of the light reflected from



**Figure 3.** Left eye fundus photograph of 30 year old man with retinitis pigmentosa showing extensive bony spicules reaching almost upto the macula along with some atrophic changes. FAF image of the same eye clearly showing the demarcation between the viable (normal autofluorescence) and the atrophic areas (hypoautofluorescence).

the retina and thus allows individual photoreceptors to be imaged.<sup>22</sup> Recent studies have shown the ability of adaptive optics-based system to image microscopic blood vessels and the cone photoreceptor mosaic. Its utility has been shown in identifying reduced cone photoreceptors in Retinitis pigmentosa.<sup>23</sup>

Three commercially available machines which incorporate some of the above recent imaging modalities are discussed further.

### Optos®

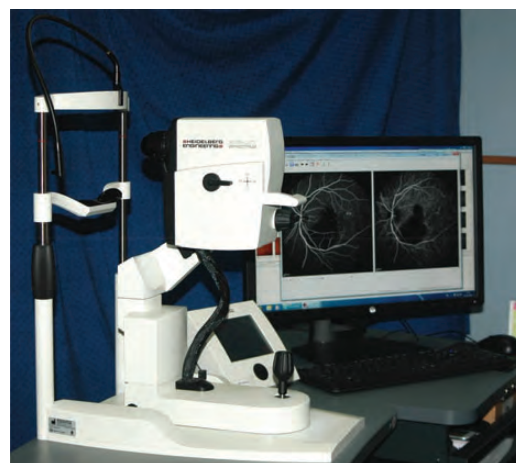
The first and one of the most widely used commercially available ultra-widefield systems is the Optos noncontact camera. The Optos system utilizes an ellipsoid mirror to produce images with approximately 200° field of view, providing an image of more than 80% of the retina in a single capture.<sup>24</sup> The Optos provides various high-resolution imaging systems with multiple software options catering to specific requirements. Also instead of white light, Optos incorporates low powered laser wavelengths that scan simultaneously. This allows viewing of the retinal substructures in their individual laser separations. The red free view scans the sensory retina up to the pigment epithelial layer whereas the choroidal view scans layers from the RPE to the choroid.<sup>25</sup> Optos also provides ultra-widefield, high-resolution angiography, enabling a simultaneous central and peripheral view of the retina. Thus the entire retinal vasculature can be imaged during the dye transit. This is particularly useful in conditions affecting periphery first like retinal vasculitis. Recent studies also support the added advantage of peripheral imaging in diabetic retinopathy, vascular occlusion, choroidal mass, Uveitis, choroidal dystrophies, retinal detachment, pediatric retinal conditions and many more disorders.<sup>26-34</sup> Wessel et al.<sup>26</sup> reported that UWFI visualizes 3.2 times more retinal surface area than the conventional seven standard fields. Also in 10% of eyes, UWFI diagnosed peripheral retinal pathology not seen on traditional fundus imaging.<sup>26</sup> Optos has wide range of ultra widefield devices depending upon the various features it provides. While the Optos 200Dx and Optos 200C provides features like color fundus photography, ophthalmoscopy along with red free and choroidal imaging, Optos Daytona has the added feature of FAF. Optos 200Tx goes further with the addition of FFA and the newly introduced Optos California includes ICG in addition to the all above-mentioned features thus making it feasible for ultrawidefield multimodal imaging.<sup>25</sup>

Despite its ability to produce dynamic widefield fundus images, the Optos Optomap® has several limitations. It requires a skilled technician to obtain peripheral images. Also unlike traditional fundus photography, Optos does not allow a

retinal view before taking the image, due to the ellipsoid mirror used for focusing the confocal ophthalmoscope. Even though it provides a very wide field of view, it is still unable to view the entire retina in one shot and is prone to miss the anterior retinal findings. The extent of imaging of the superior and inferior peripheral retina is less as compared to nasal and temporal periphery.<sup>35</sup> Also, there is a significant distortion and decreased resolution of the extreme temporal and nasal peripheral retina.<sup>29</sup> A method for correcting this peripheral distortion, when evaluating the retinal area and making measurements, has been described.<sup>29</sup> Artifacts related to structures anterior to retina like eyelashes, implanted intraocular lens, vitreous opacities are known to occur in Optos causing degradation of the quality and extent of imaging.<sup>36</sup>

### Spectralis

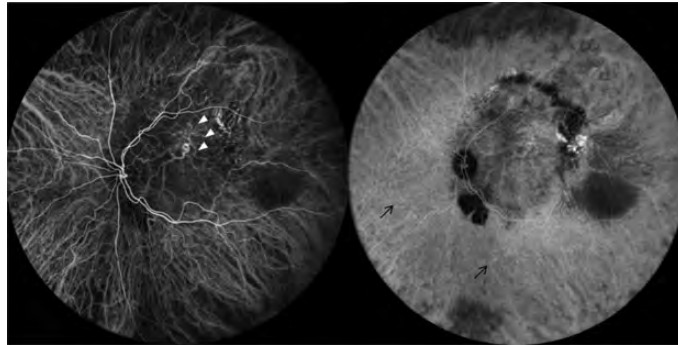
Heidelberg Spectralis (Fig. 2) has enhanced the role of fundus imaging by combining the spectral domain OCT with confocal SLO resulting in enhanced anatomical details, improved reproducibility and automatic rescan at same site at follow-up. Simultaneous multimodal imaging (Fig. 3) with FAF, infrared reflectance, FFA and ICG is also possible. Previously, the Heidelberg Spectralis® provided a 25° and 35° field of view of the retina, with the possibility of a 55° noncontact lens attachment (HRA). A different model (HRA +OCT) combines the features of HRA with spectral domain OCT and EDI OCT, thus providing an efficient tool for multimodal imaging of fundus. More recently, Heidelberg Engineering (Heidelberg, Germany) has developed a noncontact ultra-widefield angiography module for the Spectralis® and Heidelberg Retina Angiograph (HRA 2) with 105° field of view.<sup>37,38</sup> Even though



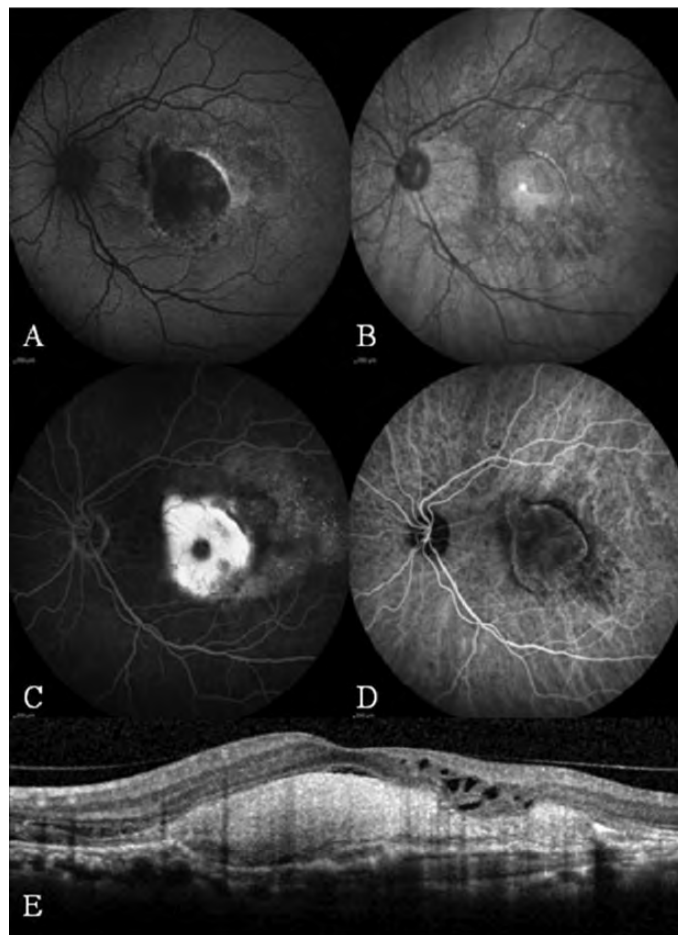
**Figure 4.** Spectralis by Heidelberg Engineering showing simultaneous FFA and ICG (multimodal imaging).

the field of view is less when compared to Optos, on qualitative analysis, the high-contrast, undistorted and evenly illuminated images of Spectralis

are found to be better and more informative than that taken by Optos.<sup>24</sup> Also image capturing is easy in Spectralis because of the use of infrared



**Figure 5.** Spectralis widefield ICG imaging done by a 150 degree non contact lens system shows a network of polypoidal vessels (arrow heads) suggestive of IPCV. The late phase of ICG shows multiple choroidal folds (black arrows) in periphery that could have been missed on a routine ICG.

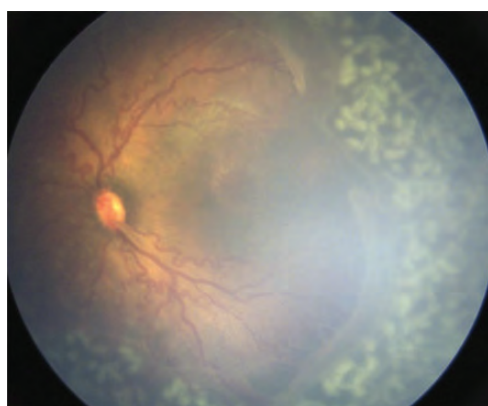


**Figure 6.** Multimodal imaging of a patient with Left eye CNVM done on Spectralis. A. FAF shows presence of hypoautofluorescent centre surrounded by a hyperautofluorescent margins. B. Infrared reflectance shows an isoautofluorescent centre with hyperautofluorescent margins. C. Late phase of FFA shows staining at the centre along with leakage at the margins suggestive of active neovascular membrane which can be appreciated as a distinct, well demarcated membrane on ICG (D). Spectral domain OCT (E) shows dense subretinal fibrin deposition with irregular RPE Bruch complex. Note presence of subretinal fluid and cystoid spaces suggestive of activity.

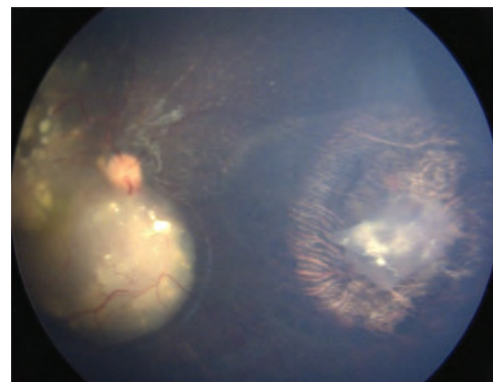
light for focusing the confocal ophthalmoscope (instead of ellipsoid mirror as in Optos), one can view the retina before taking an image.<sup>39</sup> In addition, Staurengi contact lens can be used in conjunction with the Spectralis® to provide up to 150° field of view in a single shot.<sup>7,39</sup> A recent study has shown utility of Spectralis in imaging infant fundus along with FFA to look for any retinal diseases.<sup>40</sup> One limitation of Spectralis is that instead of true color images, pseudo color images are displayed, which may not represent the exact clinical picture.

### RetCam

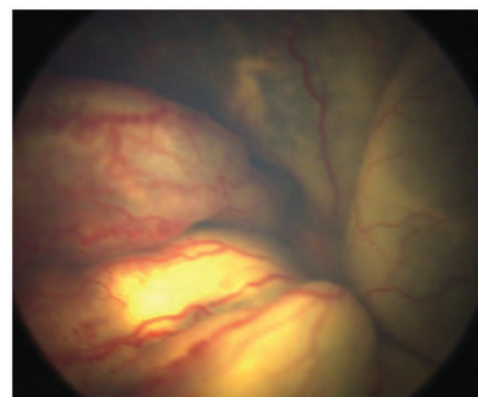
RetCam is an advanced, wide-field digital imaging system which provides good quality of ophthalmic visualization and photo documentation with great ease. It has been found to be an effective tool for immediate evaluation of pediatric ocular pathology. The newer-generation RetCam 3 provides further high-resolution digital images and can be shared electronically with an ophthalmologist or a physician and can be tracked longitudinally over time. RetCam 3 is equipped with a family of interchangeable lenses that provides a wide range of image options allowing the physician to view both anterior and posterior ocular pathology.<sup>41,42</sup> Retcam-3 has five changeable lenses: 130° (pediatric retina and adult anterior chamber), 120° (pediatric and young adult), 80°(high contrast pediatric and adult), 30° (high magnification) and Portrait (external imaging).<sup>43</sup> The major use of RetCam has been in screening, classification and follow-up of pediatric conditions like retinopathy of prematurity (ROP) (Fig. 7), Retinoblastoma (Fig. 8), Coats disease (Fig. 9) etc. It helps in identifying the appropriate intraocular group of retinoblastoma, assessing treatment response, regression patterns and to detect any recurrence. It also



**Figure 7.** RETCAM image of Lasered Stage 2 Zone I ROP with plus disease—left eye showing tortuous vessels at posterior pole. Note presence of ridge just temporal to macula and lasered avascular zone anteriorly.



**Figure 8.** RETCAM image of right eye of a child showing Intraocular Retinoblastoma undergoing treatment. Note the active tumour involving macula with calcification and another regressing tumour nasally with surrounding chorioretinal atrophy and central fish flesh appearance. RETCAM helps in documenting the treatment response by serial imaging.



**Figure 9.** RETCAM image of right eye of a young boy showing bullous exudative retinal detachment with presence of dense subretinal exudates and telangiectatic vessels confirming the diagnosis of Coats disease.

allows screening of premature infants at risk for ROP and has been shown to be an invaluable tool in resident training, parent education and photo documentation of ROP.<sup>44</sup> RetCam 3 can also be equipped with an optical light source to perform fluorescein angiography which may be helpful in differentiating between diseases like Coats and Retinoblastoma. RetCam has gained great success as a screening imaging tool in various national and international tele-ophthalmology projects such as KIDROP (Karnataka Internet-Assisted Diagnosis of Retinopathy of Prematurity), and SUNDROP (Stanford University Network for Diagnosis of Retinopathy of Prematurity).<sup>45,46</sup> RetCam in addition to fundus imaging can also be used to image and document the angle and other

anterior segment abnormalities like iris nevus, pigment dispersion/pseudoexfoliation, neovascularization etc.<sup>43</sup>

### Conclusion

Different retinal diseases require different imaging modalities for better understanding and management. The field of fundus imaging is developing rapidly and several new and exciting technologies are on the horizon which will cater to the needs of an ophthalmologist. This will help us in evolving our understanding of various disease entities thus helping us in better management of our patients.

### References

1. Yannuzzi LA, Ober MD, Slakter JS, *et al* Ophthalmic fundus imaging: today and beyond. *Am J Ophthalmol*. 2004;137:511–24.
2. Abramoff MD, Garvin MK, Sonka M. Retinal imaging and image analysis. *IEEE Trans Med Imaging*. 2010;3:169–208.
3. Behrendt T, Slipakoff E. Spectral reflectance photography. *Int Ophthalmol Clin*. 1976;16:95–100.
4. Bennett TJ, Barry CJ. Ophthalmic imaging today: an ophthalmic photographer's viewpoint – a review. *Clin Exp Ophthalmol* 2009;37:2–13.
5. Ciardella A, Brown D. Wide-field imaging. In: Agarwal A (ed.) *Fundus Fluorescein and Indocyanine Green Angiography: A Textbook and Atlas*. Thorofare: Slack Inc., 2007, pp. 79–84.
6. Pomerantzeff O. Equator-plus camera. *Invest Ophthalmol*. 1975;14(5):401–6.
7. Staurengi G, Viola F, Mainster MA, Graham RD, Harrington PG. Scanning laser ophthalmoscopy and angiography with a wide-field contact lens system. *Arch Ophthalmol*. 2005;123(2):244–52.
8. Woon WH, Fitzke FW, Bird AC, Marshall J. Confocal imaging of the fundus using a scanning laser ophthalmoscope. *Br J Ophthalmol*. 1992;76(8):470–4.
9. Castro Lima V, Rodrigues EB, Nunes RP, Sallum JF, Farah ME, Meyer CH. Simultaneous confocal scanning laser ophthalmoscopy combined with high-resolution spectral-domain optical coherence tomography: a review. *J Ophthalmol*. 2011;2011:743670. .
10. Croft DE, Van Hemert J, Wykoff CC, *et al* Precise montaging and metric quantification of retinal surface area from ultra-widefield fundus photography and fluorescein angiography. *Ophthalmic Surg Lasers Imaging Retina*. 2014;45:312–7.
11. Holz FG, Steinberg JS, Göbel A, Fleckenstein M, Schmitz-Valckenberg S. Fundus autofluorescence imaging in dry AMD: 2014 Jules Gonin lecture of the Retina Research Foundation. *Graefes Arch Clin Exp Ophthalmol*. 2015;253(1):7–16.
12. Park SP, Siringo FS, Pensec N, *et al* Comparison of fundus autofluorescence between fundus camera and confocal scanning laser ophthalmoscope-based systems. *Ophthalmic Surg Lasers Imaging Retina*. 2013;44(6):536–43.
13. Scholl HP, Chong NH, Robson AG, Holder GE, Moore AT, Bird AC. Fundus autofluorescence in patients with leber congenital amaurosis. *Invest Ophthalmol Vis Sci*. 2004;45(8):2747–52.
14. Malamos P, Masaoutis P, Georgalas I, *et al* The role of fundus autofluorescence imaging in the study of the course of posterior uveitis disorders. *Biomed Res Int*. 2015;2015:247469. .
15. Nam KT, Yun CM, Kim JT, *et al* Central serous chorioretinopathy fundus autofluorescence comparison with two different confocal scanning laser ophthalmoscopes. *Graefes Arch Clin Exp Ophthalmol*. 2015. [Epub ahead of print].
16. Burke TR, Duncker T, Woods RL, *et al* Quantitative fundus autofluorescence in recessive Stargardt disease. *Invest Ophthalmol Vis Sci*. 2014;55(5):2841–52.
17. Vujosevic S, Vaclavik V, Bird AC, Leung I, Dandekar S, Peto T. Combined grading for choroidal neovascularisation: colour, fluorescein angiography and autofluorescence images. *Graefes Arch Clin Exp Ophthalmol*. 2007;245(10):1453–60.
18. Elsner AE, Burns SA, Weiter JJ, Delori FC. Infrared imaging of sub-retinal structures in the human ocular fundus. *Vision Res*. 36:191–205.
19. Miura M, Elsner AE, Beausencourt E, *et al* Grading of infrared confocal scanning laser tomography and video displays of digitized color slides in exudative age-related macular degeneration. *Retina*. 22:300–8.
20. Gao L, Smith RT, Tkaczyk TS. Snapshot hyperspectral retinal camera with the Image Mapping Spectrometer (IMS). *Biomed Opt Express*. 2012;3(1):48–54.
21. Kashani AH, Lopez Jaime GR, Saati S, Martin G, Varma R, Humayun MS. Noninvasive assessment of retinal vascular oxygen content among normal and diabetic human subjects: a study using hyperspectral computed tomographic imaging spectroscopy. *Retina*. 2014;34(9):1854–60.
22. Roorda A, Romero-Borja F, Donnelly W Iii, Queener H, Hebert T, Campbell M. Adaptive optics scanning laser ophthalmoscopy. *Opt Express*. 2002;10(9):405–12
23. Tojo N, Nakamura T, Fuchizawa C, Oiwake T, Hayashi A. Adaptive optics fundus images of cone photoreceptors in the macula of patients with retinitis pigmentosa. *Clin Ophthalmol*. 2013;7:203–10.
24. Witmer MT, Parlitsis G, Patel S, Kiss S. Comparison of ultra-widefield fluorescein angiography with the Heidelberg Spectralis® noncontact ultra-widefield module versus the Optos® Optomap®. *Clin Ophthalmol*. 2013;7:389–94
25. <http://www.optos.com/en/Products/Retinal-imaging-products/Ultra-widefield-imaging> (6 May 2015).
26. Wessel MM, Aaker GD, Parlitsis G, Cho M, D'amico DJ, Kiss S. Ultra-wide-field angiography improves the detection and classification of diabetic retinopathy. *Retina*. 2012;32(4):785–91.
27. Wessel MM, Nair N, Aaker GD, *et al* Peripheral retinal ischaemia, as evaluated by ultra-widefield fluorescein angiography, is associated with diabetic macular oedema. *Br J Ophthalmol*. 2012;96(5):694–8.
28. Prasad PS, Oliver SC, Coffee RE, *et al* Ultra wide-field angiographic characteristics of branch retinal and hemicentral retinal vein occlusion. *Ophthalmology*. 2010;117:780–4.
29. Spaide RF. Peripheral areas of nonperfusion in treated central retinal vein occlusion as imaged by wide-field fluorescein angiography. *Retina*. 2011;31:829–37.
30. Coffee RE, Jain A, McCannel TA. Ultra wide-field imaging of choroidal metastasis secondary to primary breast cancer. *Semin Ophthalmol*. 2009;24:34–6.
31. Tsui I, Kaines A, Schwartz S. Patterns of periphlebitis in intermediate uveitis using ultra wide field fluorescein angiography. *Semin Ophthalmol*. 2009;24:29–33.
32. Kaines A, Tsui I, Sarraf D, *et al* The use of ultra wide field fluorescein angiography in evaluation and management of uveitis. *Semin Ophthalmol*. 2009;24:19–24.
33. Anderson L, Friberg TR, Singh J. Ultrawide-angle retinal imaging and retinal detachment. *Semin Ophthalmol*. 2007; 22:43–7.
34. Fung TH, Yusuf IH, Smith LM, Brett J, Weston L, Patel CK. Outpatient Ultra wide-field intravenous fundus fluorescein angiography in infants using the OptosP200MA scanning laser ophthalmoscope. *Br J Ophthalmol*. 2014;98(3): 302–4.
35. Bonnay G, Nguyen F, Meunier I, *et al* Screening for retinal detachment using wide--field retinal imaging. *J Fr Ophthalmol*. 2011;34:482–5.

36. Dunphy RW, Wentzolf JN, Subramanian M, *et al* Structural features anterior to the retina represented in panoramic scanning laser fundus images. *Ophthalmic Surg Lasers Imaging*. 2008;**39**:160–3.
37. [http://www.optech.net.au/optech\\_net005.htm](http://www.optech.net.au/optech_net005.htm) as accessed on 4 May 2015.
38. <http://www.heidelbergengineering.com/us/products/spectralis-models> as accessed on 4 May 2015.
39. Witmer M, Kiss S. Wide-field imaging of the retina. *Surv Ophthalmol*. 2013;**58**(2):143–54.
40. Fung TH, Yusuf IH, Xue K, *et al* Heidelberg spectralis ultra-widefield fundus fluorescein angiography in infants. *Am J Ophthalmol*. 2015;**159**:78–84.
41. Linder BJ. The Value of RetCam system. <http://www.claritymsi.com/international/downloads/references/TheValueofRetCam2011.pdf> as accessed on 6 May 2015.
42. <http://www.claritymsi.com/international/retcam3.html> as accessed on 4 May 2015.
43. [http://www.claritymsi.com/us/downloads/Lenses&Images\\_2009\\_f.pdf](http://www.claritymsi.com/us/downloads/Lenses&Images_2009_f.pdf) as accessed on 4 May 2015.
44. Chiang M, Melia M, Buffenn AN. Detection of clinically significant retinopathy of prematurity using wide-angle digital retinal photography—a report by the American Academy of Ophthalmology. *Ophthalmology*. 2012;**119**(6):1272–1280.
45. Vinekar A, Gilbert C, Dogra M, *et al* The KIDROP model of combining strategies for providing retinopathy of prematurity screening in underserved areas in India using wide-field imaging, tele-medicine, non-physician graders and smart phone reporting. *Indian J Ophthalmol*. 2014;**62**(1):41–9.
46. Wang SK, Callaway NF, Wallenstein MB, *et al* SUNDROP: six years of screening for retinopathy of prematurity with telemedicine. *Can J Ophthalmol*. 2015;**50**(2):101–6.

**How to cite this article** Amit BJ, Jaya Prakash V, Muna B. Techniques of Fundus Imaging, *Sci J Med & Vis Res Foun* 2015;**XXXIII**:100–107.

## Insight Ophthalmic Photography Competition

### Jaydeep Avinash Walinjkar and Mohammadarif Mulla

Ophthalmic photography is an art in itself, with the skill of the photographer and the camera used being paramount in capturing the pathology in a way that the picture conveys the message without any words. The photographer is however almost always forgotten once the photograph is taken.

With a vast spectrum of clinical cases, Sankara Nethralaya prides itself on having a very talented group of ophthalmic photographers as well as skilled amateurs. Together they contribute to an excellent documentation of disease conditions in all fields of Ophthalmology. This issue of Insight wishes to recognize their talent by publishing the results of an in house ophthalmic photography competition, open to all employees who can click a photograph (professionals as well as amateurs).

We received entries from 14 participants including professional ophthalmic photographers as well as ophthalmologists for six categories.

Category 1: Fundus photography (Single frame or Montage): including colour, red free and autofluorescence images

Category 2: Fundus fluorescein angiography

Category 3: Indocyanine angiography

Category 4: Anterior segment slit lamp photography

Category 5: Ophthalmic Smartphone photography

Category 6: Ophthalmic external photography

Each participant was allowed to send a maximum of 2 entries under each of the six categories. All the photographs received were compiled and segregated into their respective categories. They were judged by three external judges, all known for their interest in ophthalmic imaging and photography.

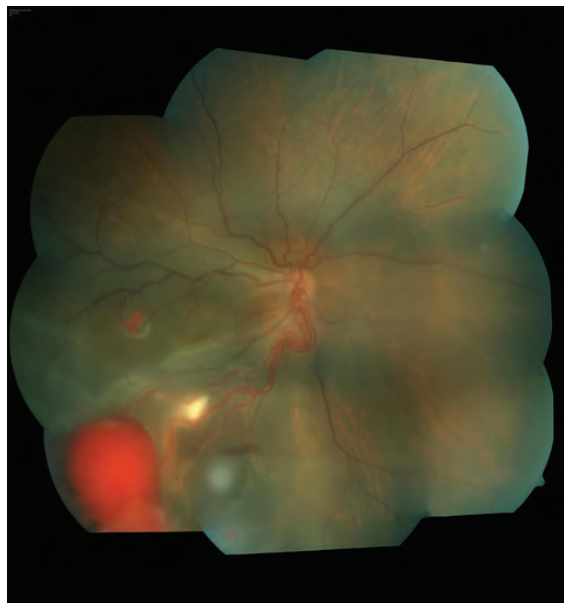**Dr Mahesh P Shanmugam**, Head, Vitreoretinal and Ocular Oncology Services, Sankara Eye Hospitals, Bangalore

**Dr Nitin Shetty**, Director, The Retina Clinic, Bangalore

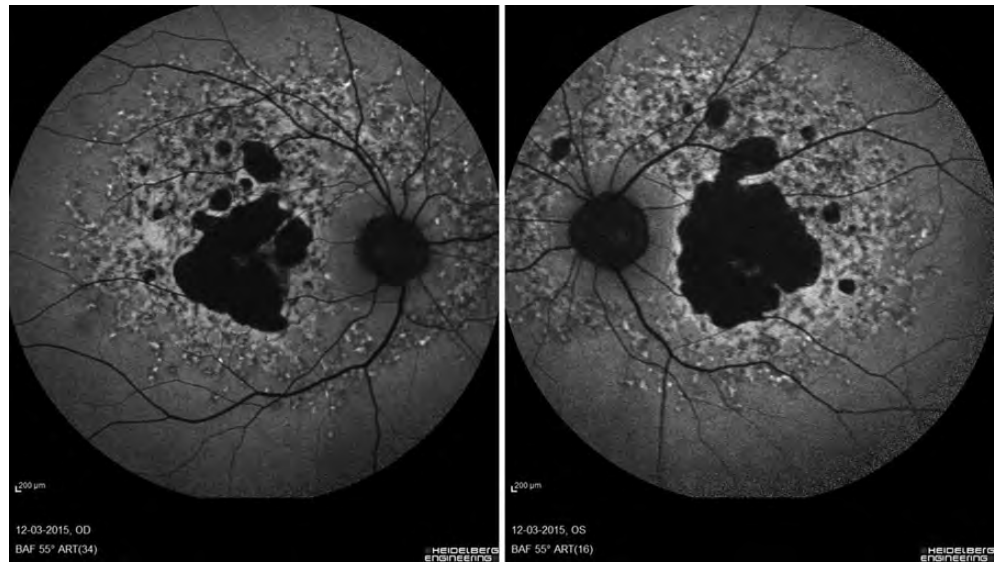
**Dr Shobhit Chawla**, Medical Director & Chief Vitreoretinal Surgeon, EYE Q-PNK Super Specialty Eye Hospitals, Lucknow

Winners were selected under each category. Each category had 2 winners with the top two scores (1st prize and 2nd prize). One photograph with the highest individual score across all the six categories was chosen for the "Best Photograph" award.

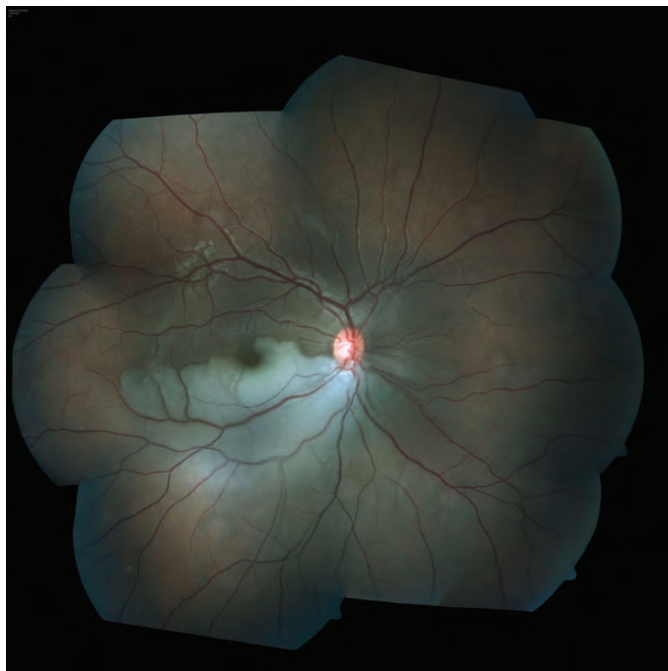#### Category: Fundus Photo



**Winner:** Mr. Chidambaram K, Sankara Nethralaya, Chennai (employee number: 1100968)



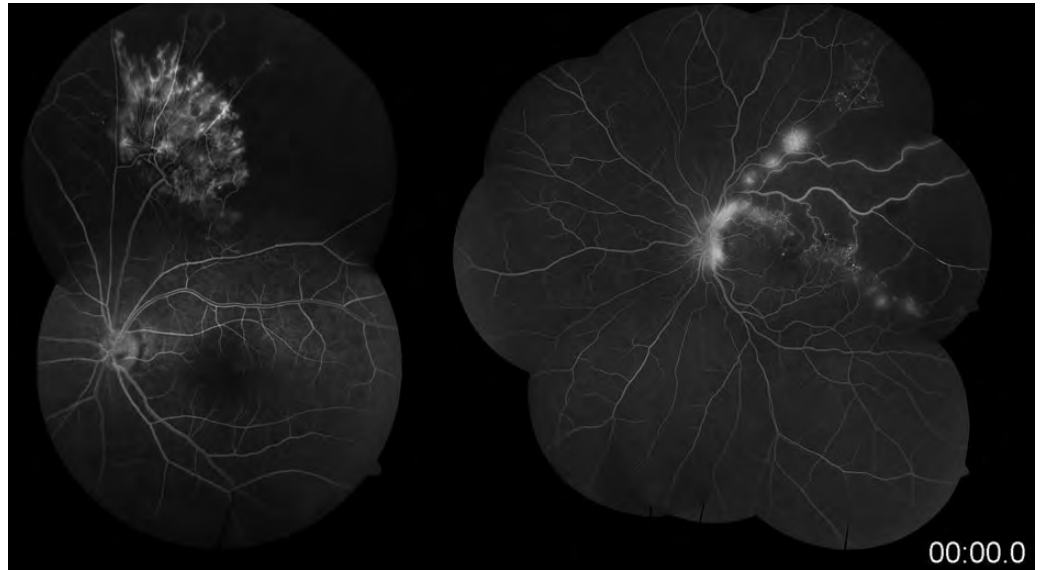
**Second Prize:** Mrs. Gouri Das, Sankara Nethralaya, Kolkata (employee number: 1102665 )



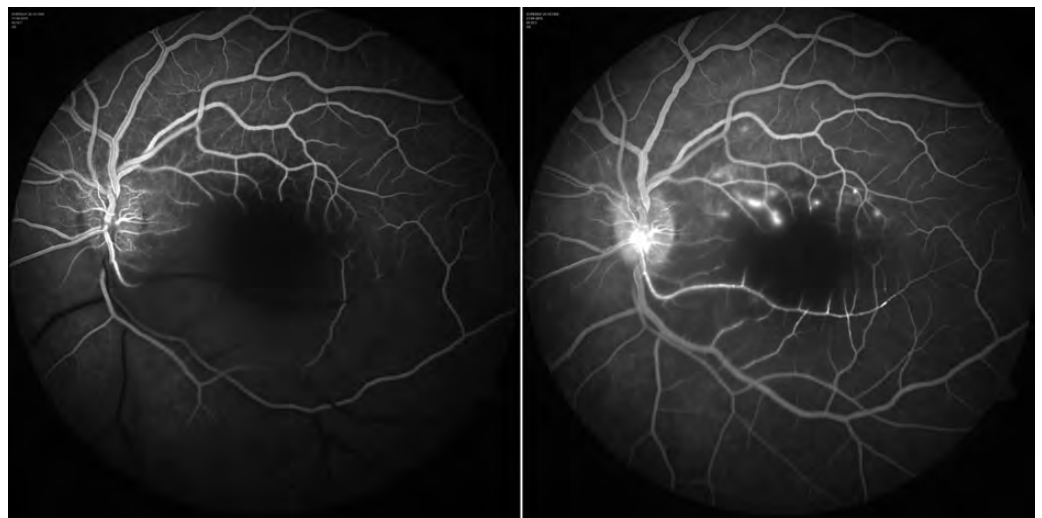
**Second Prize:** Mr. Shankar K, Sankara Nethralaya, Chennai (employee number: 1101881)



Category: Fundus Fluorescein Angiography

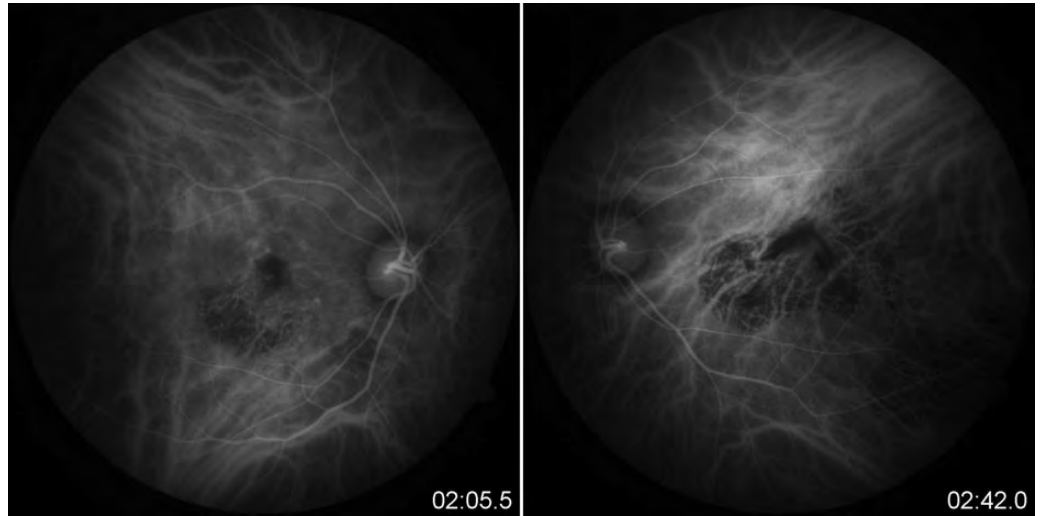


**Winner:** Thilak M, Sankara Nethralaya, Chennai (employee number: 1103580)

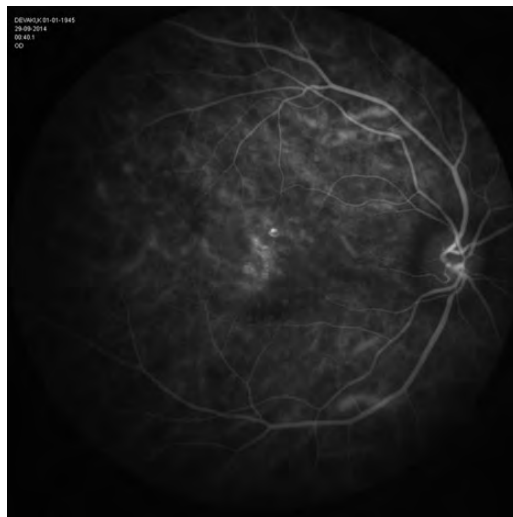

**Second Prize:** Mr. Chidambaram K, Sankara Nethralaya, Chennai (employee number: 1100968)

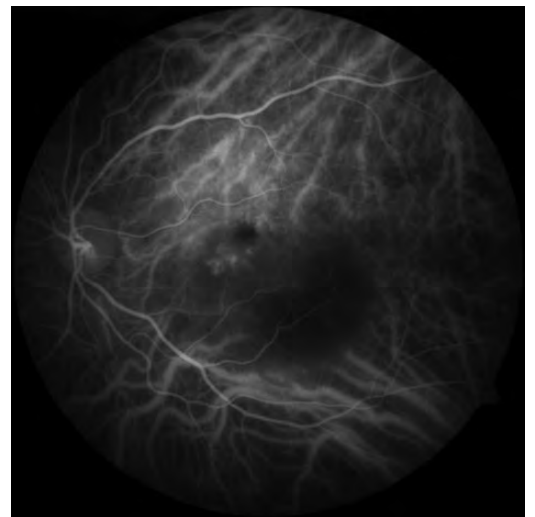
## Category: Indocyanine Green Angiography



**Winner:** Mr. Shankar K, Sankara Nethralaya, Chennai (employee number: 1101881)

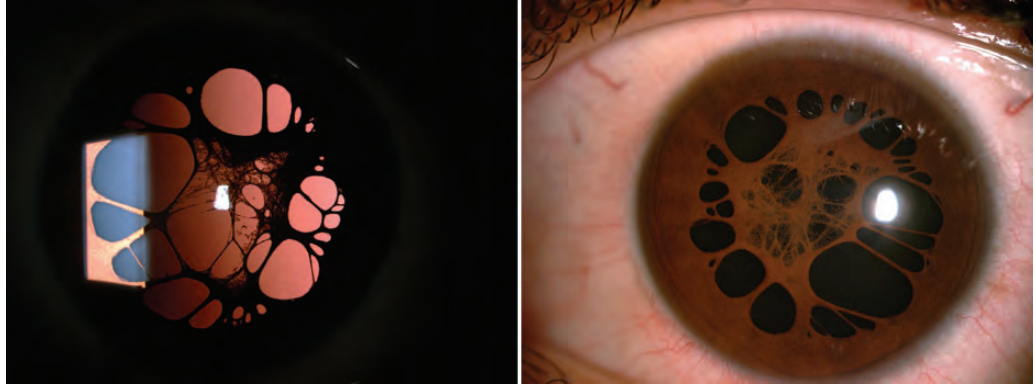


**Second Prize:** Hariharan C. S,  
Sankara Nethralaya, Chennai  
(employee number: 1103478)

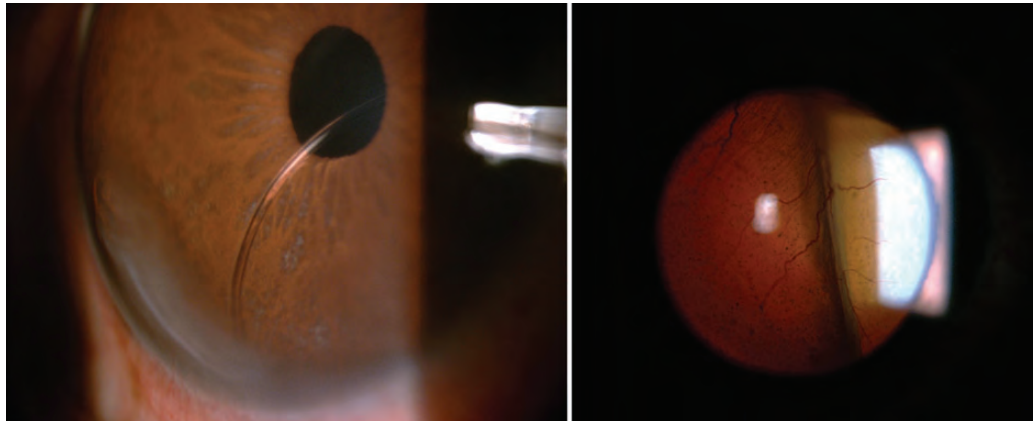


**Second Prize:** Thilak M,  
Sankara Nethralaya, Chennai  
(Employee number: 1103580)

Category: Slitlamp Photography

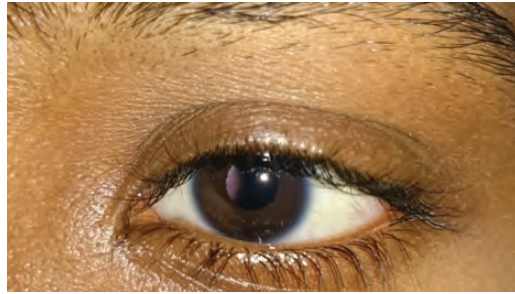


**Winner:** Mr. Shankar K, Sankara Nethralaya, Chennai (employee number: 1101881)

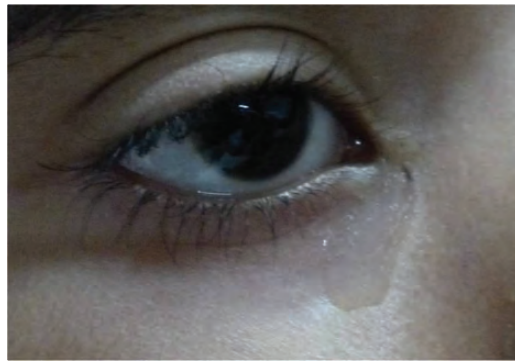


**Second Prize:** Thilak M, Sankara Nethralaya, Chennai (Employee number: 1103580)

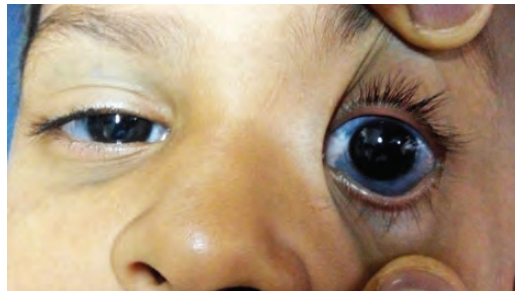Category: Smartphone Photography



**Winner:** Mr. Stephen D (Employee number: 1101758)

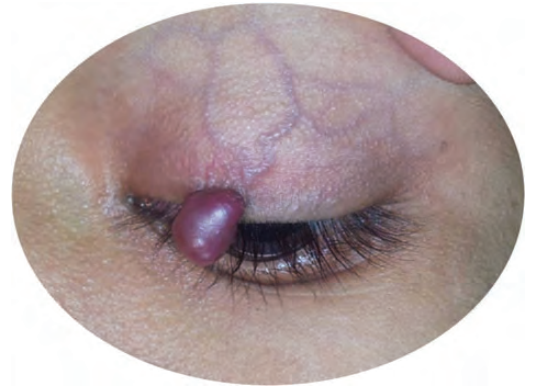


**Second prize:** Dr Shahid Alam M D (Employee number: 1101308)

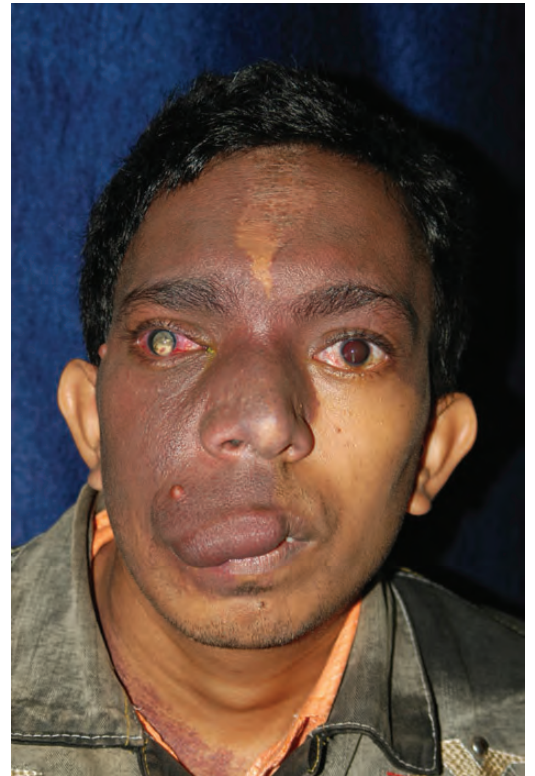

**Second prize:** Dr. R. Srikanth (Employee number: 1103997)

Category: External Photography



**Winner:** Dr Shahid Alam M D (Employee number: 1101308)



**Second Prize:** Mr. Shankar K, Sankara Nethralaya, Chennai (employee number: 1101881)

# Developing Clinical Empathy:

## *Enhancing Patients' Satisfaction*



**Tarun Sharma**

Director, Shri Bhagwan Mahavir Vitreoretinal Services, Sankara Nethralaya

**Corresponding author.**

Tarun Sharma, Director, Shri Bhagwan Mahavir Vitreoretinal Services, Sankara Nethralaya.  
Email: drtaruns@gmail.com

*The practice of medicine is an art, not a trade; a calling, not a business; a calling in which your heart will be exercised equally with your head.*

*A physician needs a clear head and a kind heart.*

### *Story unfolds...*

Many many years ago, a patient underwent a successful scleral buckling surgery; however, he developed buckle infection in the immediate postoperative period, leading to panophthalmitis and early orbital cellulitis. The eye could not be salvaged and had to be eviscerated as an emergency procedure at midnight.

The patient was relieved off the severe pain and the family went back.

Around 6 weeks later, the family returned with a gift for the doctor: a pair of trousers and a box of sweets with an invitation to visit his home whenever the doctor visits the city of joy, Kolkata!

The doctor was dumbfounded.

There he discovered how important the trust between a doctor and a patient is; and these gifts items were simply an expression of love and gratitude towards that TRUST.

### *Meet the living GOD, everyday...*

Life is a journey: a journey of everyday learning; and for a doctor, it is a learning from every patient.

This is the kind of learning that text books and medical schools do *not* include in their curriculum, this is a learning that is *not* taught in residency, this is a learning that is *not* much discussed in scientific forums.

This is a LEARNING, we as doctors, EXPERIENCE with our patients, who are indeed living GOD, as was shared by the late Dr KP Misra, a well-known cardiologist of yesteryears, in one of his teachings.

*Anyone who stops learning is old, whether at twenty or eighty.  
Anyone who keeps learning stays young.*

— Henry Ford

*Life is a journey, not a destination. Each day presents an opportunity for learning.*

## Developing Clinical EMPATHY

Well, as we all know that the practice of medicine is an art and a science.

*It is much harder to acquire the art than the science.*

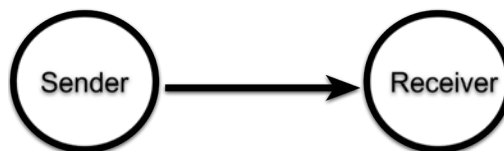The science aspect we do learn in medical schools and/or during fellowships; but to learn the art, we need to develop sensitivity: *we need to put ourselves in patients' shoes.*

Treat the patient, not just the disease; follow the patient-centered approach, and not just the disease-centered approach.

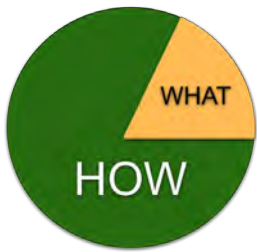*Remember that behind the retina, there is an individual; behind that individual, there is a family; behind that family, there is a neighborhood and extended family; behind the extended family, there is a network of humans, either physically or digitally and so on. Therefore, a doctor's diagnostic skill to identify the disease or surgical skill to manage the disease is just not sufficient; what is needed is to communicate in layman terms the jargon of his diagnosis, treatment options, risks or benefits and so on. For the doctor, this might be a repetition or a routine, but for a patient, it is an experience. Even for a disease that has bad prognosis, the way the information is shared, the way the patients is educated, the way the body language is used, there is tremendous satisfaction not just for the patient and his family, but to the doctor as well. It is not just sharing of the information in a monotonous voice with a stone face or not answering his queries or his questions. It is to show an empathy, clinical empathy!*

- It is to show that we are here to help you.
- It is to show that we do understand their expectations.
- It is to show that we do not dampen their hope, especially, in those challenging clinical settings wherein the outcome is rather extremely guarded.
- It is to show that we have answered all their questions.
- It is to show that we do encourage him to come back or write to us for any query they might have.
- It is to show that our body language and voice and choice of words all are in unison.

Remember in any kind of communication there are 4 components: sender (we, the doctor), the message (verbal or written), the media (phone, e-mail, oral, Skype and so on), and the receiver (the patient). Which component is the most important? Guess? QUIZ TIME!!



A: The receiver, the patient



## What Vs How:

It is not *what* you communicate, but *how* you communicate: with or without that EMPATHY.

Our skill of clinical empathy would get sharpened as we practice it.

- It builds trust.
- It strengthens one of the strongest doctor-patient relationships.
- It sustains the great rapport between a doctor and a patient.
- It brings back the hope and confidence in their minds.



Below are **10 Maxims** that could be followed so as to nurture CLINICAL EMPATHY:

1. Greet the patient first and try to judge his anxiety toward his ailments or expectation after the treatment.
2. Evaluate how much he/she knows about the diagnose or treatment; add to his/her knowledge pool.
3. Share the treatment options; help a patient make the right choice or decision.
4. Use a simple drawing, clinical images or other tests as a tool to reinforce your verbal explanation.
5. As you enhance their knowledge of how the normal eye works, their understanding of the abnormality will also increase and they would be a great partner in their evaluation and treatment.
6. Do not lose your temper, if the same questions are being asked by him or family members repeatedly. And always end the consultation with a simple sentence: *Is there any other question or query you have?*
7. Do not blame the 'other' doctor for his present condition or his ill fate.
8. However, if all goes well: give the credit to him: 'you are one of the luckiest patients of the day who has made such good visual recovery, much more than our expectations: Congratulations!  
I am very pleased. God is kind to both of us.'
9. Words have power, healing power, use them to your advantage, use them to heal the wound and spirit.
10. Do not hesitate to put a hand on the shoulder; and silently make a prayer for his well-being.

Last, but not least: go down memory lane and recall, when you did not know retinal surgery or when you were just learning, the patient also did not know about you and your skill but he surrendered himself to you. The learning we got from so many hundreds and thousands of patients is that there is no way we can say thank you to them; but now that your hands are stable, you are more mature, you can definitely hold those trembling hands.

Many a times we all like to emulate people and their lofty goals; however, only a few achieve them. Hence, it is good to know the barriers that hinders clinical empathy. There are three barriers:

- ☛ **Time Barriers:** need to examine more and more patients; it adds to anxiety and a kind of psychological barrier.
- ☛ **Considering Empathy, not an important issue:** focusing on just science, the treatment and surgery, just the disease leaving out the patient as a whole.
- ☛ **Negative emotions of physicians:** when patients ask many questions or share the views of another doctor or not happy with the outcome.

*Studies have shown that number one complaint patients have about their doctors is the perception that they simply don't listen. Therefore, the first step towards learning is to become a GOOD Listener.*

*Did You know that there is as much Wisdom in listening, as there is in speaking?!!*

So, enjoy the freedom & journey of learning to imbibe the great skill - **CLINICAL EMPATHY** - of becoming a great doctor.

*Medicine is a calling, not a business.*

*A calling which exacts from you, at every turn, self-sacrifice, devotion, love, and tenderness to your fellow-men. Once you get down to a purely business level, your influence is gone and the true light of your life is dimmed. The physician's work is not, and must not, always be financially rewarding.*

*REMEMBER: Work is our worship which we must do with three attributes: Sincerity, Dedication and utmost Love.*



## List of fellows trained in Shri Bhagwan Mahavir Vitreoretinal Services, Sankara Nethralaya (1979–2013)

Dr M S Ravindra	Dr Rajiv Mirchia	Dr Debabrata Dutta	Dr Seemant Raizada
Dr Narinder K Lath	Dr Shabhit Chawla	Dr Alay Banker	Dr Vinata Rajendran
Dr Sitaramanjanyalu B	Dr Lalit Mohan Shukla	Dr Monoj Govila	Dr Joshua George
	Dr Vatsal S Parikh	Dr Zia Ul Hasan	Dr Rajani R Battu
Dr Mahesh J Patel	Dr Sunil N Parikh		Dr Sanowar Hossain
Dr Manju Kulkarni	Dr SeetharamanJeneyulu	Dr Partha Biswas	Dr Candace Mary D'souza
Dr Sridhar Rao B	Dr Hareh Asnani		
Dr Vasanth N Patel		Dr Amal Deb	Dr Gooty Agraharam Satish
	Dr Sanjiv Hansraj	Dr Malay Chaturvedi	Dr Neeraj Sanduja
Dr Prema Padmanabhan	Dr Vinod Jain	Dr Prashant Keshav Bhawankule	Dr Ramesh Raghavendran Sivaraj
Dr Madhav R Honnatti	Dr Ravi Matani	Dr Suresh Ramchandani	Dr Satyen Deka
Dr Hemanth Doshi	Dr Gupta R P	Dr Sheik Mehub Sobhan	Dr Madhushudan
	Dr Ravishankar K V	Dr Ajay Dudani	
Dr K Ravishankar	Dr Challa J K	Dr Devinder Singh Virdi	Dr Mohammad Delwar Hossain
Dr Syed Gulam Ahmed	Dr Nitin G Prabhu Desai	Dr Rajat Agarwal	Dr Parveen Kharbanda
Dr Mihika Sashital	Dr Kohli C M		Dr Niren R Dongre
Dr Rajini Kantha		Dr Murgesh Kanubhai Kotia	Dr Milan D Thakkar
	Dr Preetam Singh	Dr Suhas Jijabrao Sonawane	Dr V K Dhull
Dr D Ramamurthy	Dr Anjali Nicholson	Dr Vaidya Ashish Rabindra	Dr Balasubramanian
Dr Lingam Gopal	Dr Mehul C Shah	Dr Agrwal Santosh Hanuman	Dr Sourav Sinha
Dr Mythili Sriram	Dr Rajasekar D Kotrappa	Dr Raj Kumar Gupta	
Dr A Giridhar	Dr Atul Ursekar	Dr Shishir Narain	Dr Anand Subramanyam
Dr Cyrus Shroff	Dr Surendra Basti		Dr Saurabh Luthra
Dr Madhivanan Natarajan	Dr Buddi Rajiv	Dr Salil Arab Mehta	Dr Malhar Soni
	Dr Gargee Gupta	Dr Dhanshree Arun Deshpande	Dr Suman
Dr Aruna Parekh	Dr Premalatha Agarwal	Dr Bhushan Uttam Khare	Dr Pankaj Singhal
Dr Jyotirmoy Biswas	Dr Sanjeev Doshi		
Dr Sunil K Bhandari		Dr Anil Kumar Sharma	Dr Pathengay Avinash
Dr Arun Elhence	Dr Paritosh A Kamdar	Dr Nishikant Jaywant Borse	Dr Tapan Kumar Samanta
Dr S Natarajan	Dr Sanjay Srivastava	Dr Shroff Rahul Ashok	Dr Prasan M Rao
	Dr Anil Verma	Dr Gautam Panda	Dr Bikash Basu
Dr Vinay Nangia	Dr S A Md O S Kutubi		Dr Preetam Manmohan Samant
Dr Saraf P K	Dr Upsham Goyal	Dr Debashis Das	
Dr Hiren Saikia	Dr Vipin Kumar VIG	Dr Jajneswar Bhunia	Dr Sandeep P Thakur
Dr Anand Saxena	Dr Kumar K S	Dr Sangeet Mittal	Dr Mahesh G
Dr Tarun Sharma		Dr Sunil Mehra	Dr Ekta Anand
Dr Vinay Kumar Garg	Dr Pramod S Bhende	Dr Ashwini C K	Dr Ajeet Madhav Wagle
Dr Brahma Reddy K	Dr Gajendra Chawla		Dr Surbhit Choudhry
		Dr Sandeep K Saha	Dr Praveen R Murthy
Dr Vimal Sarup	Dr Shammi Kapoor	Dr Pratik Ranjan Sen	Dr Ravi Krishna N
Dr Tashwala J B	Dr P Mahesh Shanmugam	Dr Randeep Sharma	
Dr Ramesh K	Dr Muna Ganesan	Dr Rajesh Gupta	Dr Madhav Rao
Dr Vijaya R	Dr Puneet Gupta	Dr Surendra Shetty	Dr Swati Agarwal
Dr Bhatt N S	Dr Mahesh Panwar	Dr Mufazzal I	Dr Rajiv Raman
Dr Sharad Rastogi	Dr Sandip Mitra		
Dr Siddarthan V	Dr Ashok Monga	Dr Girish S Rao	Dr Salil Gupta
	Dr Shobana Nair P K	Dr Tushar Kanti Sinha	Dr Shah Nitant Arun
Dr Sharma B P	Dr Jaishankar	Dr Prashant Saikia	Dr Bhavsar Kaushal Bipinchandra
Dr Deepak Khosla	Dr Murlidhar S T	Dr Bibhuti Bhushan	Dr Mohammed Nizamuddin S H
Dr Mohan Rajan	Dr Roysarkar T K	Dr Naresh Yadav	Dr Kasinathan
Dr Lokesh Gupta			Dr Prathima Kathil
Dr Rajiv Thakore	Dr Pradip K Mohantha	Dr Nitin S Shitut	Dr Krishnamurthy
Dr Ranjan Mukherjee	Dr Ahmed S U	Dr Manoj	Dr Hitendra Mehta
Dr Manoj Bhatt	Dr Radha Rani Sharma	Dr Byanju R N	Dr Padmaja Kumari Rani
	Dr Nitin S Shetty	Dr Sumeet Chopra	
Dr Karobi R Lahiri	Dr Vinit Sah	Dr Neelam Kumari Upadhyay	Dr Manisha Agarwal
Dr Sunil Kumar Sah	Dr Onik Moyong	Dr Sandeep Vasudeo Mondkar	Dr Girish A Gadre
Dr Jayantha Chowdhry	Dr Lalitendu Satpathy		Dr Rajeev K Reddy

(Continued)

## List of fellows trained in Shri Bhagwan Mahavir Vitreoretinal Services, Sankara Nethralaya (1979–2013)

Dr Sribharghava	Dr Radha R Das	Dr Tandava Krishnan P	Dr Bikramjit P Pal
Dr Pooja Sinha	Dr Ashish Rawal	Dr Nishant Vijay Radke	Dr Sagar S Bhuibhar
Dr Vikas Khetan	Dr Himanshu Deshmukh	Dr Ramesh Venkatesh	Dr Vishal Rameshkumar Raval
Dr Debajit Deka	Dr Shailaja S	Dr Lala Akhundova	Dr Lakshmi Kuniyal
		Dr Mahesh P Uparkar	Dr Chinmay Prakash Nakhwa
Dr Sachin B Kabre	Dr Gullapalli V Ramkumar	Dr Karthik R Meda	Dr Arindam Roy
Dr Amit Nagpal	Dr Mahesh P Uparkar	Dr Swapnesh Deepak Sawant	Dr Chtralekha De
Dr Sumita Sharma	Dr Arun Bharghava	Dr Parthopratim Dutta Majumder (Uvea & Medical retina)	Dr Vijay Pratap Singh Tomar (Uvea & Medical retina)
	Dr Ramakant Kankara	Dr Harshali Subhash Kamat (Medical Retina)	
Dr Nishank Mittal	Dr Sheena Liz Mani		Dr Gaurav Mathur
Dr Ramesh N Patil	Dr Somendra Pratap Chaudhary		Dr Md Salman Md Saleh Kazi
Dr Chetan Rao	Dr Bhavin J Patel		Dr Rekha S
Dr Parag Chandrasekhar Apte	Dr Swakshyar Saymya Pal	Dr Alok Ashwinbhai Kathiara	Dr Mansi Kishnani
Dr S Pradeep	Dr Hari Narayan Prasad	Dr James Subratkumar Adams	Dr Eesh Nigam
Dr Vasudev Chakravarty	Dr Sanjiv Maru	Dr Maneesh Dhupper	Dr Vivek Arora
Dr Sriram Gopal		Dr Atheeshwar Das	Dr Vanuli Bajpai (Medical Retina)
Dr Anuj Gogi	Dr Ketan Vijay Jathar	Dr Ravi Rupsingh Dekate	Dr Arvind Babu C (Uvea & Medical retina)
	Dr Vishal Mohan Rathore	Dr Shalini Singh	Dr Shormin Shohelly Shipa (Uvea & Medical retina)
Dr Ramana Kumar P J		Dr M Nivean	
Dr G Sunil	Dr Manavi D Sindal	Dr Sudipta Das	
Dr Maneesh M Bapayee	Dr Daraius Shroff	Dr Deepak Agarwal	
Dr Pukhraj Rishi	Dr Abhishek Ragunandan Kothari	Dr Roopleen (Uvea & Medical retina)	Dr V Jayaprakash
Dr Rupak Kanti Biswas	Dr Madhusudan Dinesh Davda	Dr Renu Dhasmana	Dr Bindu K Appukuttan
Dr Unnikrishnan Nair	Dr Subhankar Sri Pal		Dr Aashraya Pritviraj Karpe
Dr Arti Rupalia Pankaj	Dr Aditya Verma		Dr Pradeep Kumar Panigrahi (SNK)
		Dr Aditi Gupta	Dr Abhinandan N Patil
Dr V S Prakash	Dr Krishnendu Nandi	Dr Kadri Venkatesh	Dr Subha Laxmanan
Dr K Nandakumar	Dr G Suganeswari	Dr Anshul Goyal	
Dr Vikrant Sharma	Dr Aradhana Shriram Kadekar	Dr Harshali Subhash Kamat	Dr Vishal Rajan Sharma
Dr Ankur Gupta	Dr Ambatipudi Srinivas	Dr Brahadeesh Subramaniam	Dr Sherran Raveendran
Dr Rajendra Kumar Thakur	Dr Chintamani Madhave Khare	Dr Pallavi Gaurishankar Sarate	Dr Vishnu Suryaprakash
	Dr Jay Kumar Chhablani	Dr Sayalee Tatyrao Lahane	Dr Himabindu Adusumilli
Dr Balbir Khan	Dr Swagata Sarkar	Dr Vishal Suresh Kakhandki	Dr Vishal V Kulkarani
Dr Cheriya Shane Mathew		Dr Kumar Saurabh	Dr.Sukanya A (Medical Retina)
Dr Sarita Shetty	Dr Anupama B (Medical Retina)	Dr Sireesha Pasupuleti (Uvea & Medical retina)	
Dr Teena Agarwal	Dr Shah Bhavesh Jagadishkumar	Dr Akash Patel (Medical Retina)	Dr Deepak N Bhojwani
Dr Anshu Arora	Dr Manmath Kumar Das		Dr Abhishek
Dr Hemalatha B C	Dr Shafiq Jafferji	Dr Jeepalem Sumanth Reddy	Dr Barsha Sarma
Dr (MAJ) Sandeep Shankar	Dr Vimal Kundanmal Parmar	Dr Sabyasachi Somnath Sengupta	Dr Debmalya Das (SNK)
Dr Ruchi Juneja	Dr Manoj S Khatri	Dr Md Arif Abdulrab Mulla	Dr Arshi Ahmed (Uvea & Medical retina)
Dr Amol Ashok Wankhede		Dr Jaydeep Avinash Walinjkar	
Dr Saban Horo	Dr Chinmaya Amulyanath Sahu	Dr Yogesh Devidas Patil	Dr Abhishek Dixit
	Dr Rupak Roy	Dr Nitish Mahajan	Dr Pracheer Ranjan Agarwal
Dr Sumeet Jain	Dr Sudhir Gorakhnath Sudrik	Dr Subhajit Das	Dr Swetha Palla (Uvea & Medical retina)
Dr Ashok Natarajan	Dr Badami Nagaraj Kalpana	Dr Sandhya Hegde	Dr Meenakshi V (Medical Retina)
Dr Sheshadri V Mahajan	Dr Prasad Anand Kamat	Dr Amit Basia	Dr Chinmayi Vyas (Medical Retina)
Dr Shana Waz Kazi	Dr Vishal Agrawal	Dr Aparna A C (Uvea & Medical Retina)	Dr Anindya Kishor Majumder (Uvea & Medical Retina, SNK)
Dr Shaileen Dushyantbhai Parikh	Dr Sarath Ravi	Dr Sukant Pandey	
Dr Sharad Chandraprakash Rai	Dr Shankaralakshmi (Uvea & Medical retina)	Dr Myna Achar (Medical Retina)	
	Dr Narendran Muthukrishnan		
Dr Arindam Chakravarti	Dr Hajee Hussein Frog		
Dr Mayank Dutta			
Dr Tapas Ranjan Padhi			
Dr R Vijayakumar			

# Shri Bhagwan Mahavir Vitreoretinal Services

## Sankara Nethralaya



**Standing (Left to right):** Dr. Vinata Muralidharan, Dr. Debamalya Das, Dr. Eesh Nigam, Dr. Mohammadarif Mulla, Dr. Vadivelu Jaya Prakash, Dr. Pukhraj Rishi, Dr. Pramod Bhende, Dr. Jaydeep Avinash Walinjkar, Dr. Rajesh P, Dr. Rajiv Raman, Dr. Aditya Verma

**Sitting (Left to right):** Dr. Parveen Sen, Dr. Chetan Rao, Dr. Muna Bhende, Dr. Vikas Khetan, Dr. Lingam Gopal, Dr. Pradeep Susvar, Dr. Tarun Sharma, Dr. Sukanya A, Dr. Suganeswari G, Dr. Veena Bhaskaran, Dr. Ekta Rishi